

# Dental Anatomy

## Lec.1

### Introduction

Dental anatomy is that field of anatomy dedicated to the study of human tooth structures.

#### Nomenclature

Dent- = tooth or teeth

Dental= anything related to teeth

Heterodont which means different shaped teeth.

Diphyodont which means the person who has two sets of teeth; deciduous teeth(primary teeth) and permanent teeth.

#### The Deciduous Teeth

Usually there are no teeth present in the mouth at birth, but in fact many teeth in various stages of development are found in the jaws.

After birth (post natal period) the eruption of deciduous teeth begins at six months and continues till two and half years ( $28 \pm 4$  months).

The deciduous teeth stay in mouth until the permanent teeth start its eruption at about six years of age when the transition to the permanent dentition begins.

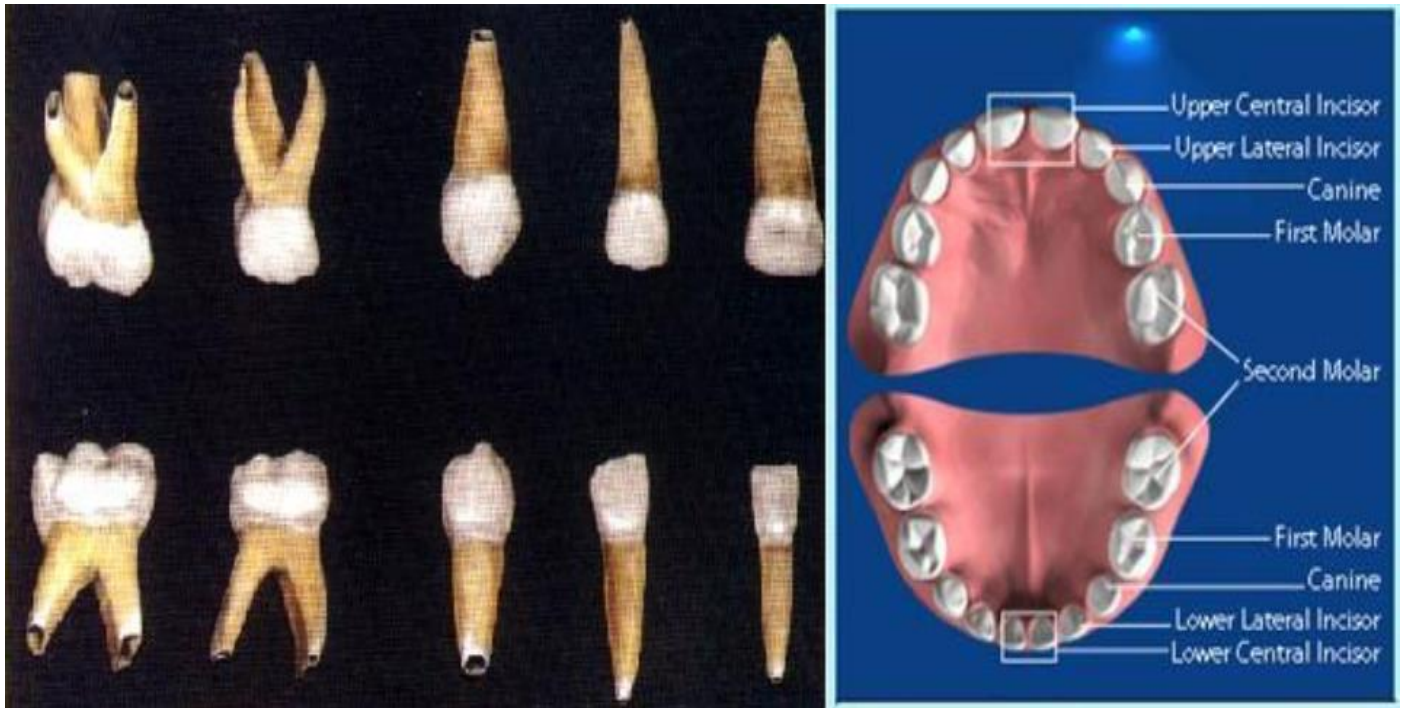
The deciduous teeth are 20 in number. They have the following formula:

$I \ 2 \ 2 \ C \ 1 \ 1 \ M \ 2 \ 2 = 10$  (For each side)

I=Incisors (central and lateral).

C=Canine.

M=Molars (first and second).



**Figure (1):Deciduous dentition**

### **The permanent teeth**

**At the age of six years, the transition to permanent dentition starts with the emergence and eruption of the first permanent molars and this followed by shedding of the deciduous teeth and continues with the emergence and eruption of the remaining permanent teeth. The whole process of eruption requires about 20 years to be completed. The number of permanent teeth including third molars when present is 32.**

**$I \ 2 \ 2 \ C \ 1 \ 1 \ P \ 2 \ 2 \ M \ 3 \ 3 = 16$  (For each side)**

**I=Incisors (central and lateral).**

**C=Canine.**

**P=Premolars (first and second).**

**M=Molars (first, second and third).**

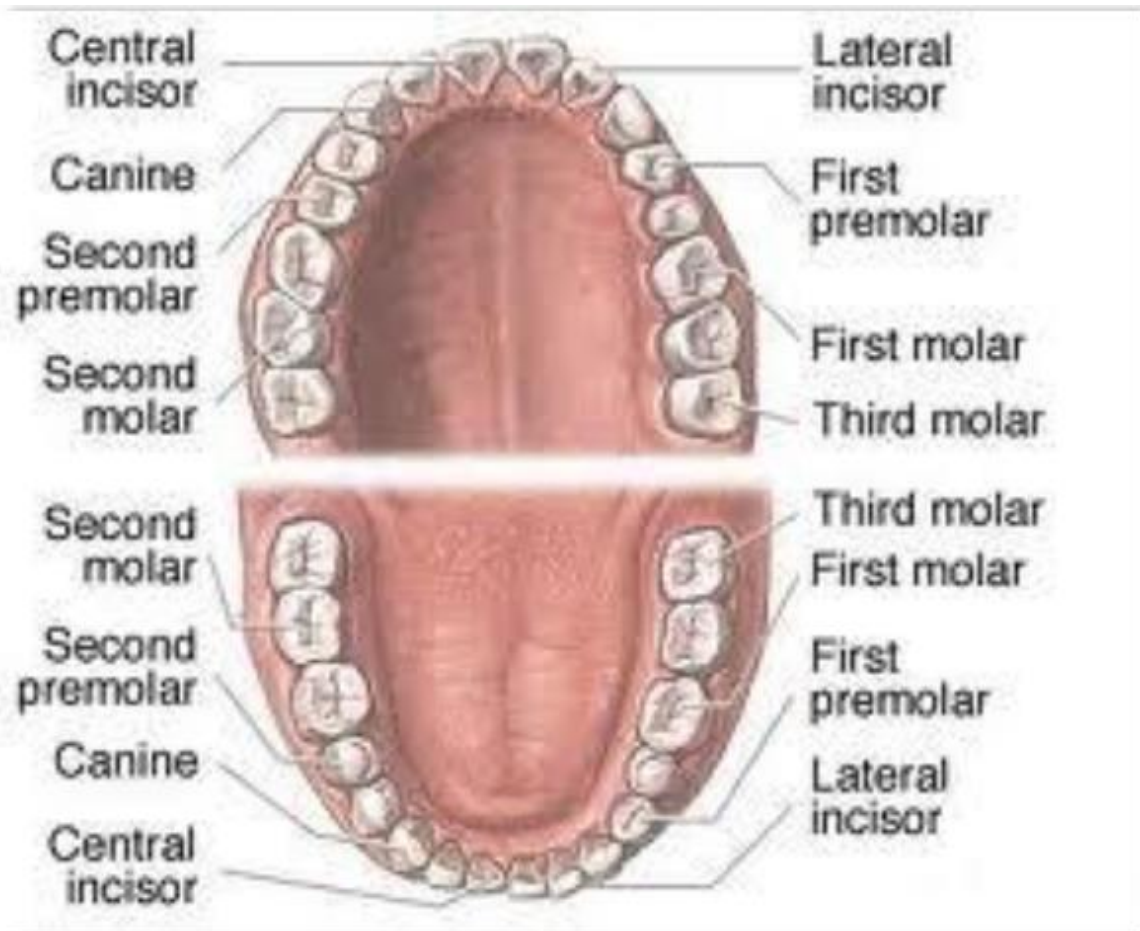


Figure (2):Permanent dentition

### *Anterior and posterior teeth*

There are two groups of teeth which is:

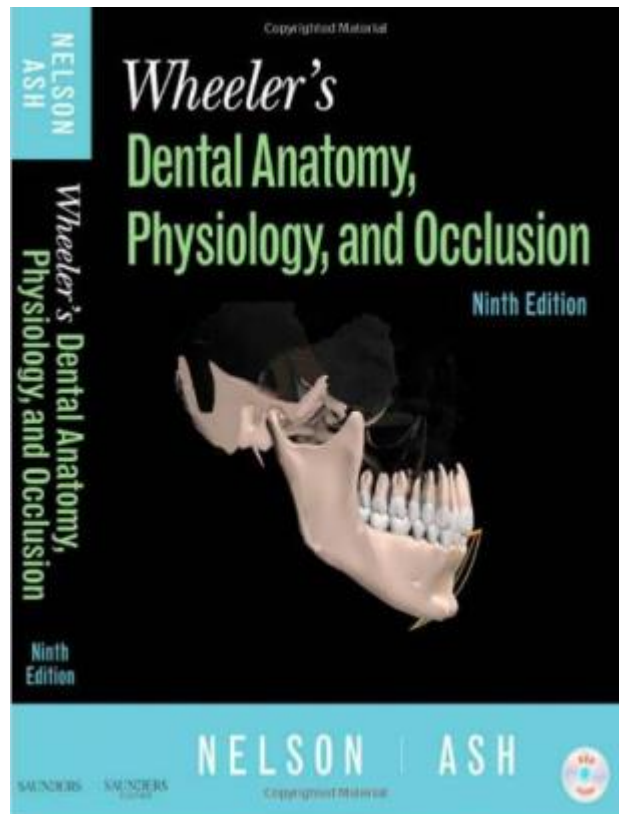
1. Anterior teeth which include the incisors and the canines.
2. Posterior teeth which include the premolars and molars.

### *The jaw*

The jaw is the bone that is responsible for carrying the teeth. There are two jaws:

1. The upper jaw which is fixed, and is called *Maxilla*.
2. The lower jaw which is movable and is called *Mandible*.

For further reading you can read the book below



# Dental Anatomy

## Lec.2

### TOOTH NUMBERING SYSTEMS

The teeth numbering system is designed to develop the standard reference principle for each particular tooth. There are three different methods have been employed throughout the teeth numbering history, and only two of them get mostly used nowadays.

#### 1.Universal notation system

##### A. Permanent teeth:

##### Maxillary

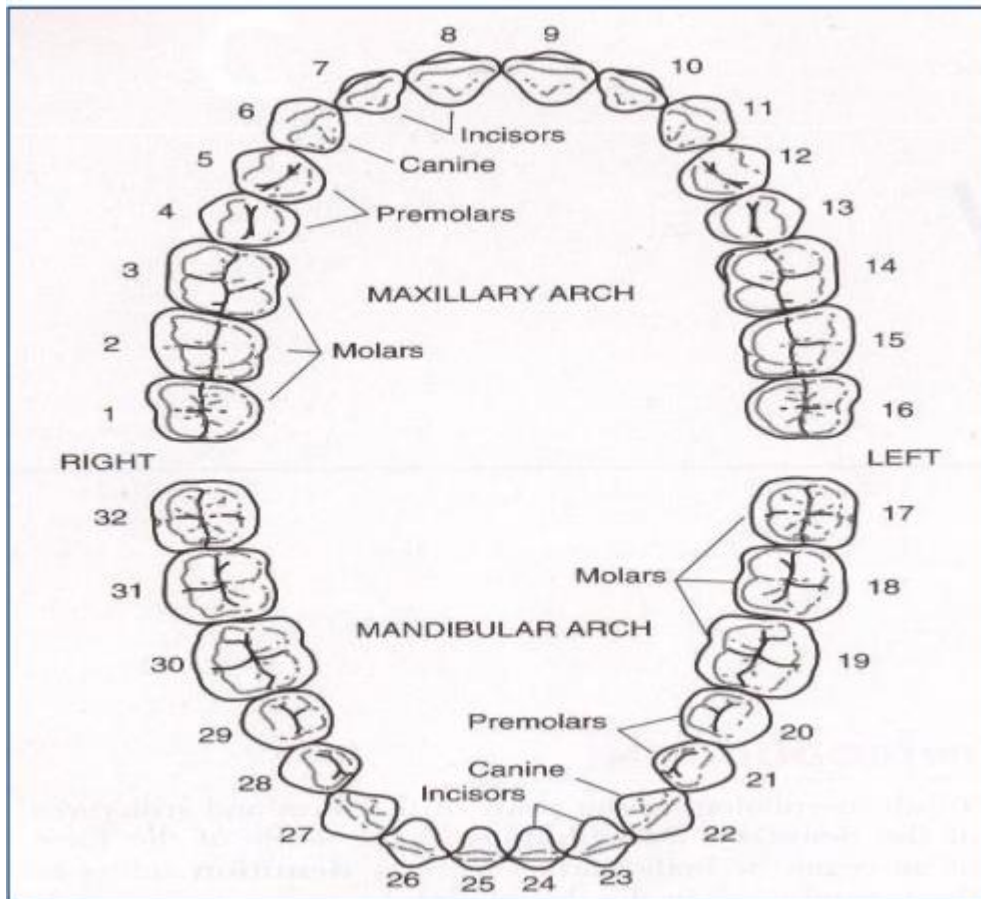
right	1 2 3 4 5 6 7 8	9 10 11 12 13 14 15 16	Left
	32 31 30 29 28 27 26 25	24 23 22 21 20 19 18 17	

##### Mandibular

**#11: Permanent maxillary left canine.**

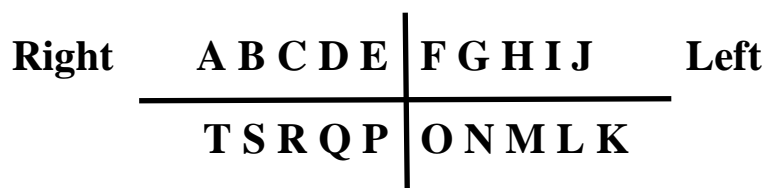
**#29: Permanent mandibular right second premolar.**

**#8: Permanent maxillary right central incisor.**



**B.Deciduous teeth**

**Maxillary**



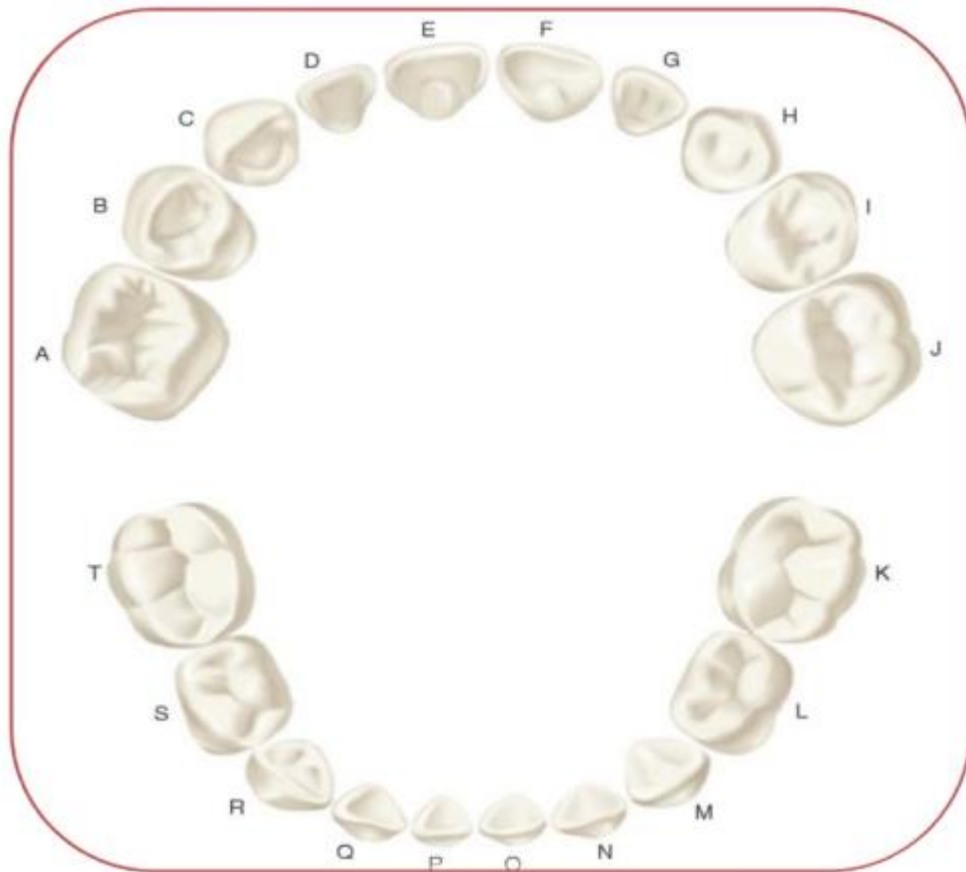
**Mandibular**

**Examples:**

**#B:Deciduous maxillary right first molar.**

**#O:Deciduous mandibular left central incisor.**

**#D:Deciduous maxillary right lateral incisor.**



## 2. Palmer notation system

### A. Permanent teeth:

#### Maxillary

Right	8 7 6 5 4 3 2 1	1 2 3 4 5 6 7 8	Left
	8 7 6 5 4 3 2 1	1 2 3 4 5 6 7 8	

#### Mandibular

Examples:

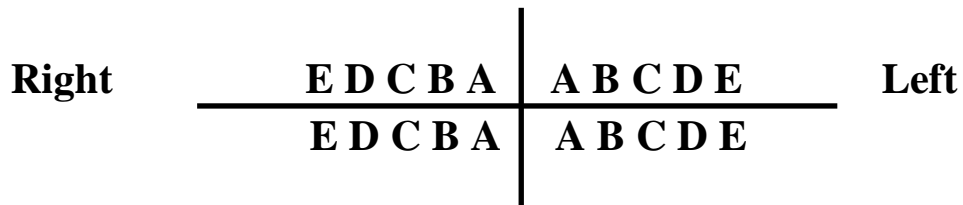
**6** Permanent maxillary right first molar.

**┌ 3 Permanent mandibular left canine.**

**└ 8 Permanent maxillary right third molar.**

*B. Deciduous teeth*

**Maxillary**



**Mandibular**

**Examples:**

**└ D Deciduous maxillary right first molar.**

**┌ C Deciduous mandibular left canine.**

**└ E Deciduous maxillary right second molar.**



### 3.FDI (Federation Dentaire International)

#### *A. Permanent teeth*

Upper Right							Upper Left									
18	17	16	15	14	13	12	11		21	22	23	24	25	26	27	28
48	47	46	45	44	43	42	41		31	32	33	34	35	36	37	38
Lower Right							Lower Left									

#### *B. Deciduous teeth*

Upper Right					Upper Left					
55	54	53	52	51		61	62	63	64	65
85	84	83	82	81		71	72	73	74	75
Lower Right					Lower Left					

### Crown and Roots

Each tooth has its own crown and root. The enamel is covering the tooth crown and root of the tooth is being covered with cementum and they join at the cemento-enamel junction (CEJ) or cervical line. The four tooth tissues are enamel, dentin, cementum and pulp. The first three tissue are called as hard tissues but the last one as

soft tissues. The major bulk of the tooth is dentin.

**Dental pulp**: is the soft tissue of the tooth and located in the pulp chamber and pulp canal.

**Pulp chamber** : is that part of dental pulp in the crown.

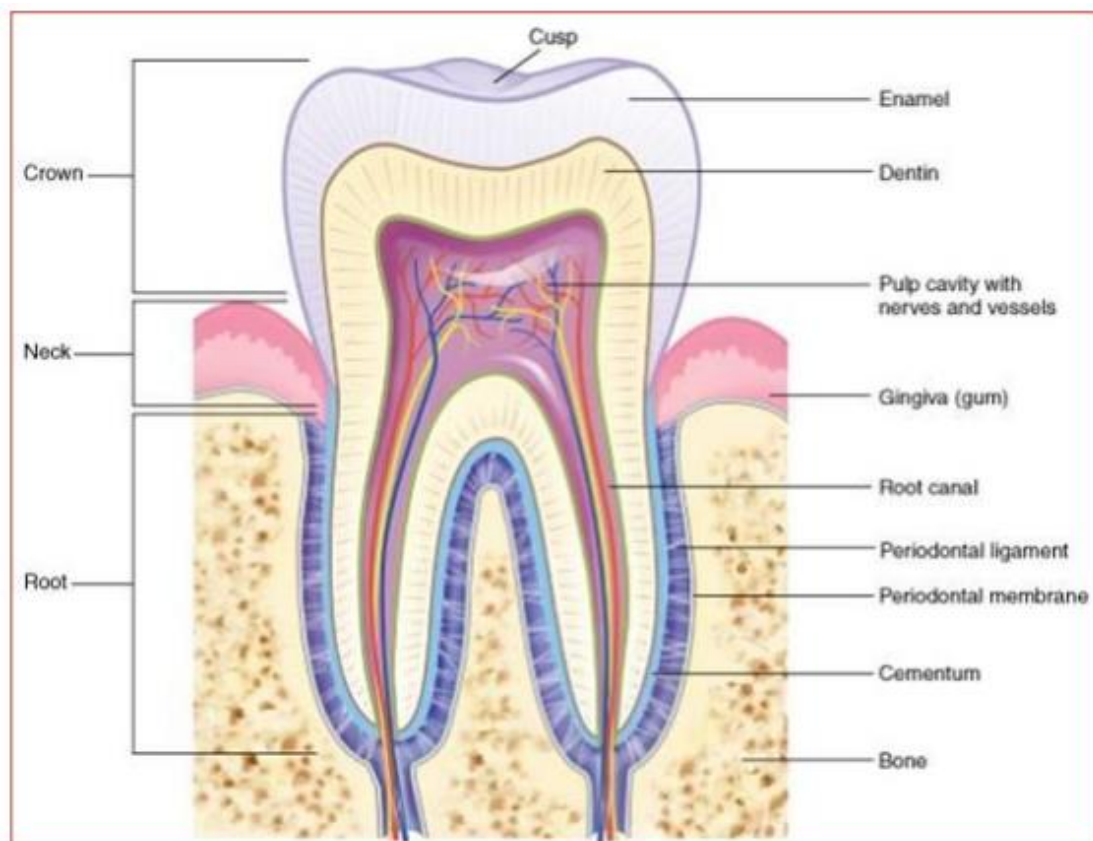
**Pulp canal** : is that part of dental pulp in the root.

*The pulp chamber are continuous with the pulp canal and collectively called as the "pulp cavity".*

**Anatomical crown** : is the portion of the tooth that covered by enamel .

**Clinical crown** : is the portion of the tooth that is obviously visible in the mouth.

In a healthy person the anatomical crown is larger than the clinical crown.



**Figure (1):Crown and root.**

**The number of roots:**

- 1. Single root: present in all anterior teeth, mandibular premolars and maxillary second premolar.**
- 2. Two roots with bifurcation: in mandibular molars and maxillary first premolar. The site of division of the tooth root is known as furcation.**
- 3. Three roots with trifurcation: in maxillary molars.**

**Surfaces and ridges:**

The crowns of incisors and canines have four surfaces and ridge, while the crowns of premolars and molars have five surfaces.

The surfaces are:

**1. Labial surface: refers to the surface which is toward the lip in incisors and canines (in anterior teeth).**

**2. Buccal surface: refers to the surface which is toward the cheek in premolars and molars (posterior teeth).**

The labial and buccal surfaces could be termed as the "**facial surfaces**".

**3. Lingual surface: refers to the surface which is facing the tongue (all teeth).**

**4. Occlusal surface: refers to the surface of the posterior teeth coming in contact with the teeth in the opposite jaw during closing the mouth.**

In anterior teeth, this surface is called "**incisal ridge**".

**5. Proximal surface: refers to the surface of the tooth facing toward adjacent teeth in the same dental arch.**

**a. Mesial surface: refers to the surface which is facing toward the median line.**

**b. Distal surface: refers to the surface which is facing away from the median line.**

All teeth have their mesial surfaces touching the distal surfaces of the adjacent tooth except the maxillary and mandibular central incisor (both permanent and deciduous). The area of the mesial and distal surface that touch its neighbor in the arch is called the "contact area".

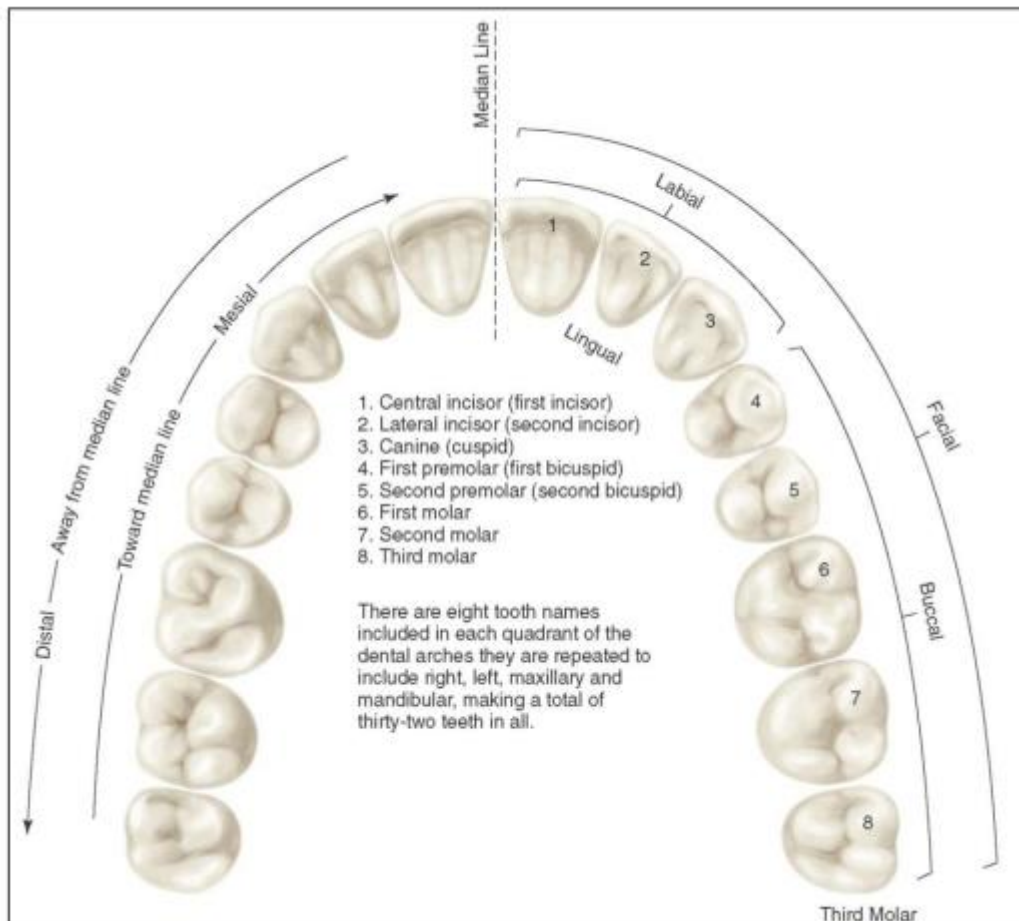


Figure (2):Application of nomenclature.

**Division of the crown into thirds:**

For description, the crown and the root are divided into thirds according to the position of the surface.

**Line angle:** it is formed by the junction of two surfaces and get its name from these surfaces. example:mesio-labial line angle.

**Point angle:** it is formed by junction of three surfaces and

get its name from these surfaces. Example:mesiologo-  
incisal point angle.

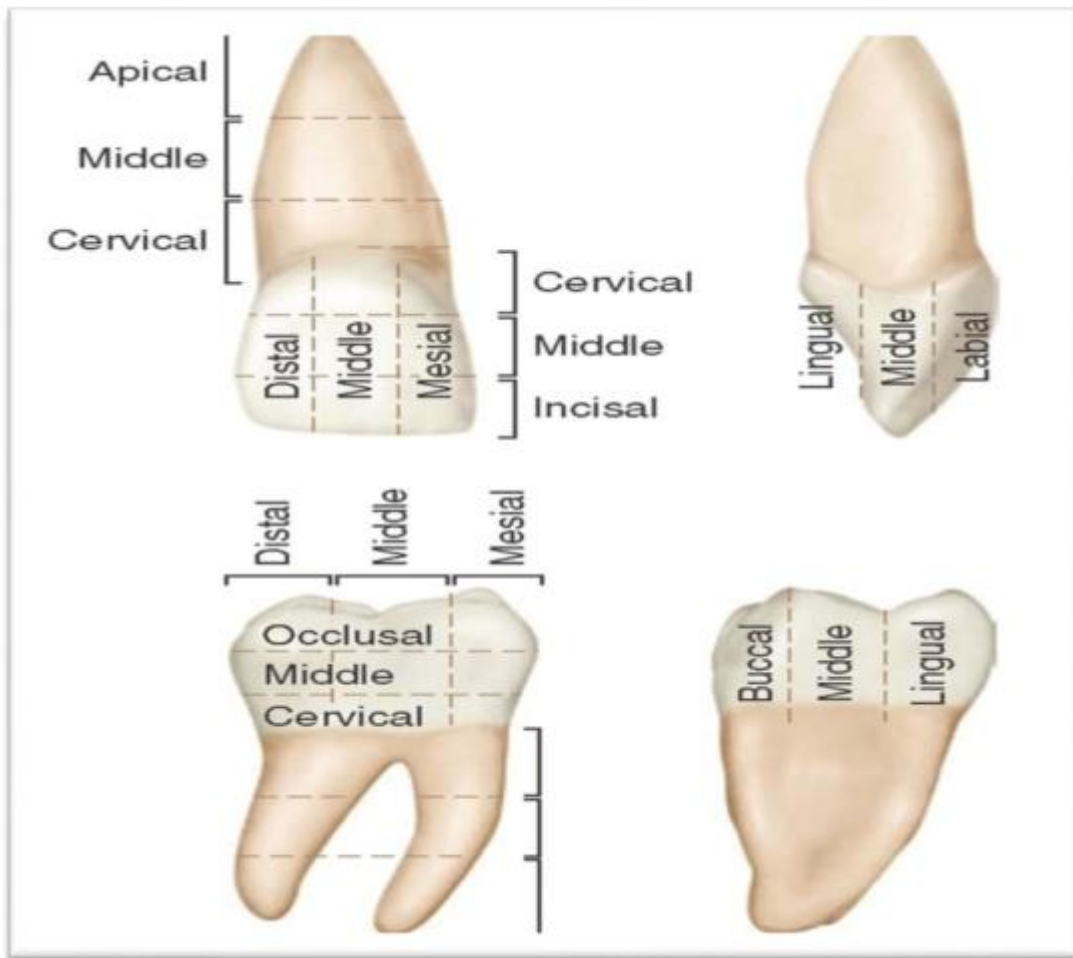
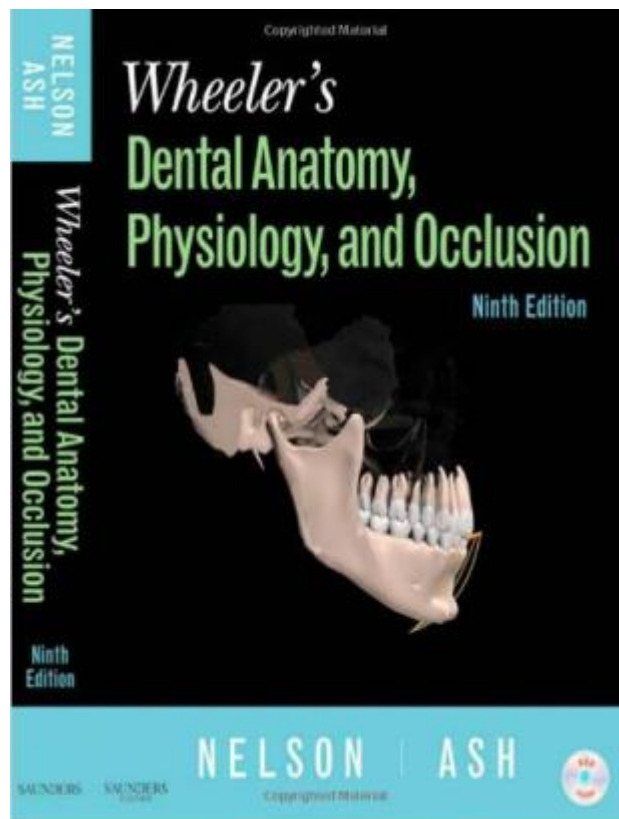


Figure (3):Divisions of crown and root of the tooth

**For further reading you can read the book below**



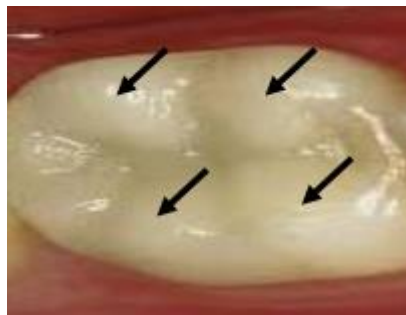
# Dental Anatomy

## Lec.3

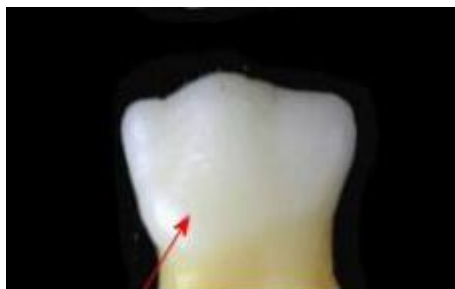### **Anatomical landmarks**

In order to study an individual tooth in a correct way, we must be able to distinguish all landmarks of importance by name, these include:

**1.Cusp:** it is an elevation or mound on the crown portion of a tooth and forming a divisional part of the occlusal surface. It contributes to a significant portion of the tooth's surface and named according to its site.



**2.Tubercle:** it is a smaller elevation on some portion of the crown as a result of an extra formation of enamel. These are deviations from the typical form.

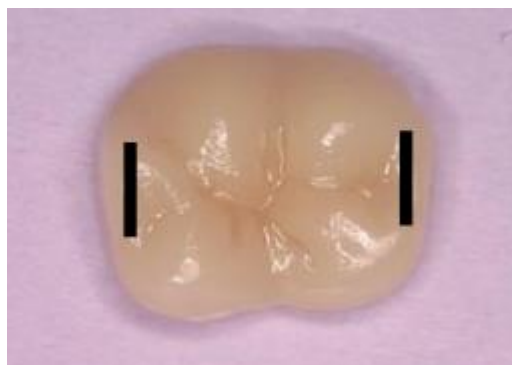

**3.Cingulum (latin word for girdle):** it is the lingual lobe of the anterior teeth. It forms up the bulk of the cervical third of the lingual surface. Its convexity mesiodistally resembles a girdle encircling the lingual surface at the cervical third. Frequently, it is identifiable as an inverted V-shaped ridge.



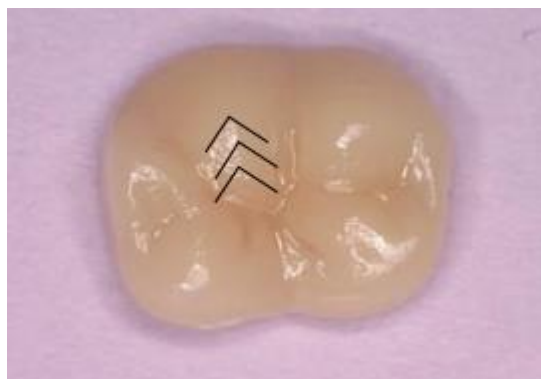**4.Ridge:** it is any linear elevation on the surface of a tooth and is named according to its location ( e.g. buccal ridge, incisal ridge, marginal ridge).

**a.Marginal ridge:** these are rounded borders of enamel that formed the mesial and distal margins of the lingual surfaces of the incisors and canines and the mesial and distal margins of the occlusal surfaces of premolars and molars.

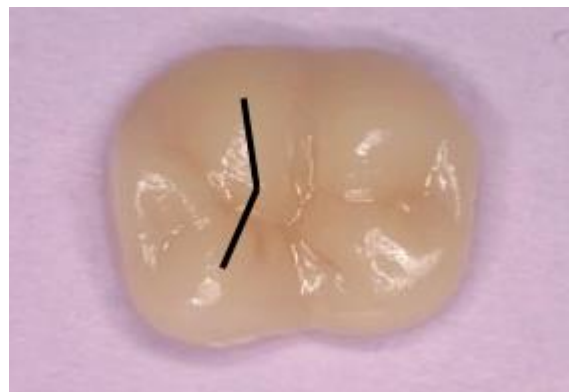



**b.Triangular ridge:** it descends from the tips of the cusps of molars and premolars toward the central part of the occlusal surfaces. It got this name because the slopes of each side of the ridge are inclined to mimic a two sides of a triangle. They are named after the cusps to which they belong, e.g. the triangular ridge of the buccal cusp of the maxillary first premolar.

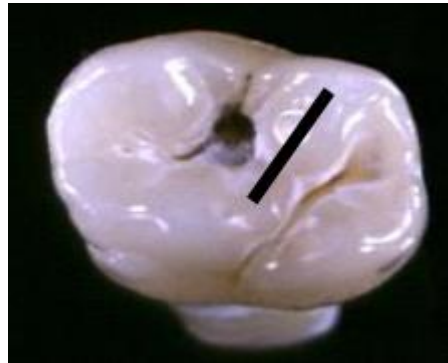

**c.Transverse ridge:** it is the union of two triangular ridges crossing transversely the surface of a posterior tooth.



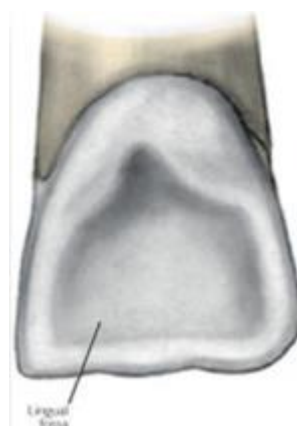**d.Oblique ridge:** it is a ridge crossing the occlusal surfaces of maxillary molars in an oblique way. It is formed by the

**union of the triangular ridge of the distobuccal cusp and the distal cusp ridge of the mesiolingual cusp.**

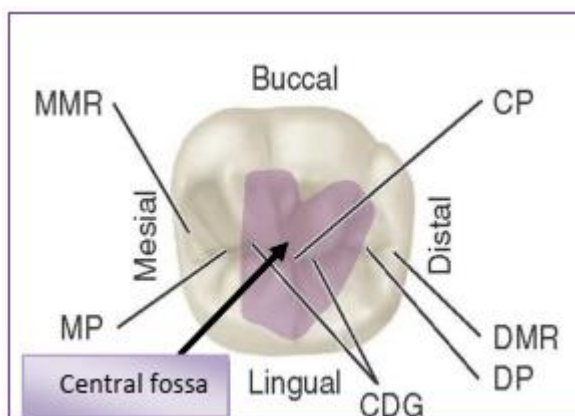


**5.Fossa:it is an irregular depression or concavity.**

**a.Lingual fossa: it is located on the lingual surface of anterior teeth.**

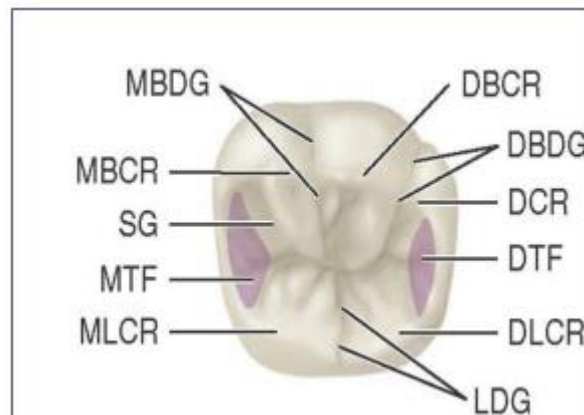


**b.Cenrtal fossa: it is located on the occlusal surface of molar.**

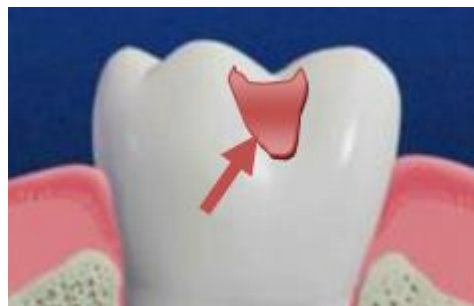

**MMR:**mesial marginal ridge.  
**DMR:**distal marginal ridge.  
**MP:**mesial pit. **DP:**distal pit.  
**CP:**central pit. **CDG:**central developmental groove

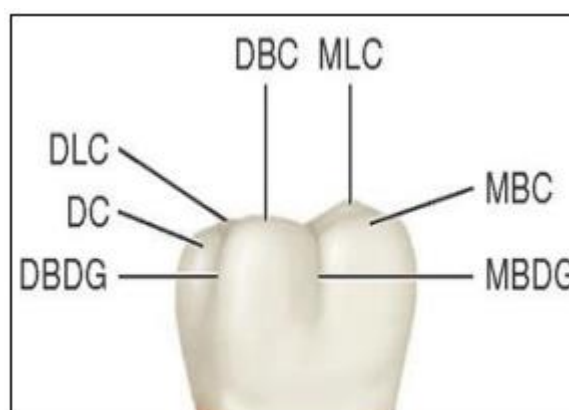
**c.Triangular fossa:** it is located on the occlusal surfaces of molars and premolars, mesial or distal to marginal ridges.



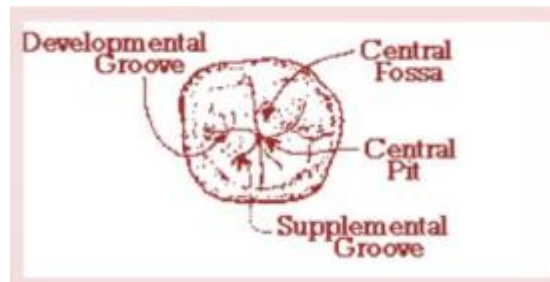
**6.Sulcus:** it is a long depression or valley in the surface of a tooth between ridges and cusps, the inclines of which meet at an angle. A sulcus has a developmental groove at the junction of its inclines.



**7.Developmental groove:** it is a shallow groove or line between the primary parts of the crown or root.

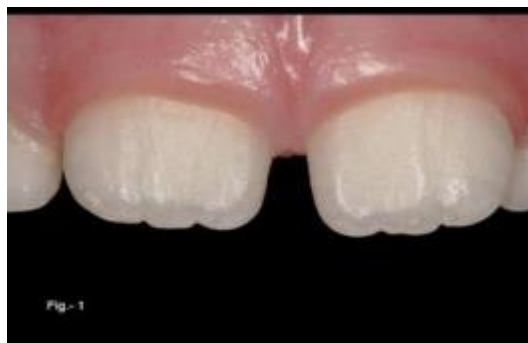

**8. Supplemental groove:** it is a less distinct, shallow linear depression on the tooth surface, but is supplemental to a developmental groove and does not mark the junction of primary parts of tooth.




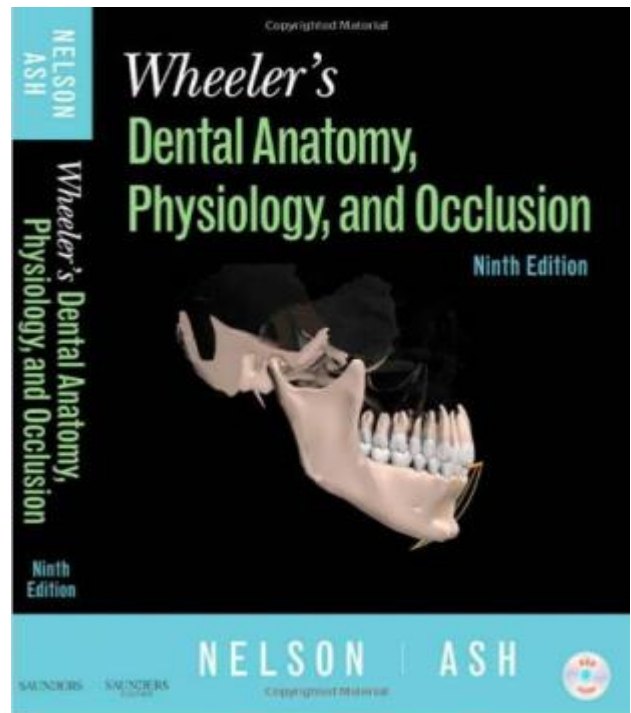
**9. Pit:** it is a small pinpoint depression located at the junction of developmental grooves or at terminals of those grooves, e.g. central pit is a term used to describe landmark in the central fossa of molars where developmental grooves join.

**10. Mamelon:** it is any one of the three rounded protuberances that is presenting on the incisal ridges of newly erupted incisor teeth.



**11.Lobe:** it is one of the primary sections of formation in the development of the crown. Cusps and mamelons are representative of lobes.

For further reading you can read this book



# Dental Anatomy

## Lec.4

### PERMANENT MAXILLARY INCISORS

Maxillary incisors are four in number. The major function of incisors is to incise or cut food during mastication. The maxillary central incisor is larger than the lateral incisor.

#### Characteristic features of incisors crown

1. These teeth have incisal ridge and edge.

*Incisal ridge* is that portion of the crown which forms up the complete incisal portion.

*Incisal edge* is created when an angle is made by the occlusal wear which produces a flattened surface linguo-incisally, sometimes called the "*incisal surface*" which joined with the labial surface.

2. Presence of mamelons.

3. Marginal ridges of are longitudinally extended.

4. Lingual fossa.

5. Cingulum.

#### Principles identifying features of permanent maxillary central incisor

1. It is the widest anterior tooth mesiodistally.

2. Straight mesial outline and rounded distal outline.

3. It has a square or rectangular appearance.

4. Sharp mesioincisal angle and rounded disto-incisal angle.

5. Mamelons on the incisal ridge (in newly erupted teeth).

6. Well marked marginal ridges, lingual fossa and well developed cingulum.

7. Single tapered root.

#### Labial Aspect

1. The mesial surface outline is slightly convex with the crest of curvature (representing the contact area) near the mesio-incisal

angle.

2. The distal outline is more convex than the mesial outline with the crest of curvature being at the junction between the incisal third and middle third.

3. The incisal outline in newly erupted teeth has elevations called Mamelons. With age they will wear off and straight incisal outline is seen.

4. The cervical outline of the crown follows a semicircular direction with the curvature directed toward the root.

5. The root is cone shaped with a blunt apex. It is 2-3mm longer than the crown.

6. A line drawn through the center of the root and the crown tends to parallel the mesial outline of the crown and root.

### Lingual Aspect

1. The crown and the root taper lingually, therefore, mesio-distal dimension of the lingual surface is narrower than that of the labial surface.

2. Below the cervical line there is a smooth convexity called cingulum which is confluent with raised marginal ridges mesially and distally.

3. Incisally there is the lingual portion of the incisal ridges. Between this ridges and the marginal ridges and the cingulum, a shallow concavity called the lingual fossa is present.

### Mesial Aspect

1. The crown is triangular in shape with the base at the cervix and the apex at the incisal ridge.

2. A line which bisect the crown will bisect the root. The incisal ridge of the crown is therefore on a line with the center of the root. This alignment is characteristic of maxillary central and lateral incisors.

3. The labial outline is slightly convex.

4. The lingual outline of the crown is convex at the cingulum then becomes concave at the mesial marginal ridge then slightly convex at the incisal ridge.

5. The cervical outline curves incisally more than any surface on any tooth, about 3-4 mm.

**6. The root from mesial aspect is cone-shaped, and the apex is bluntly rounded.**

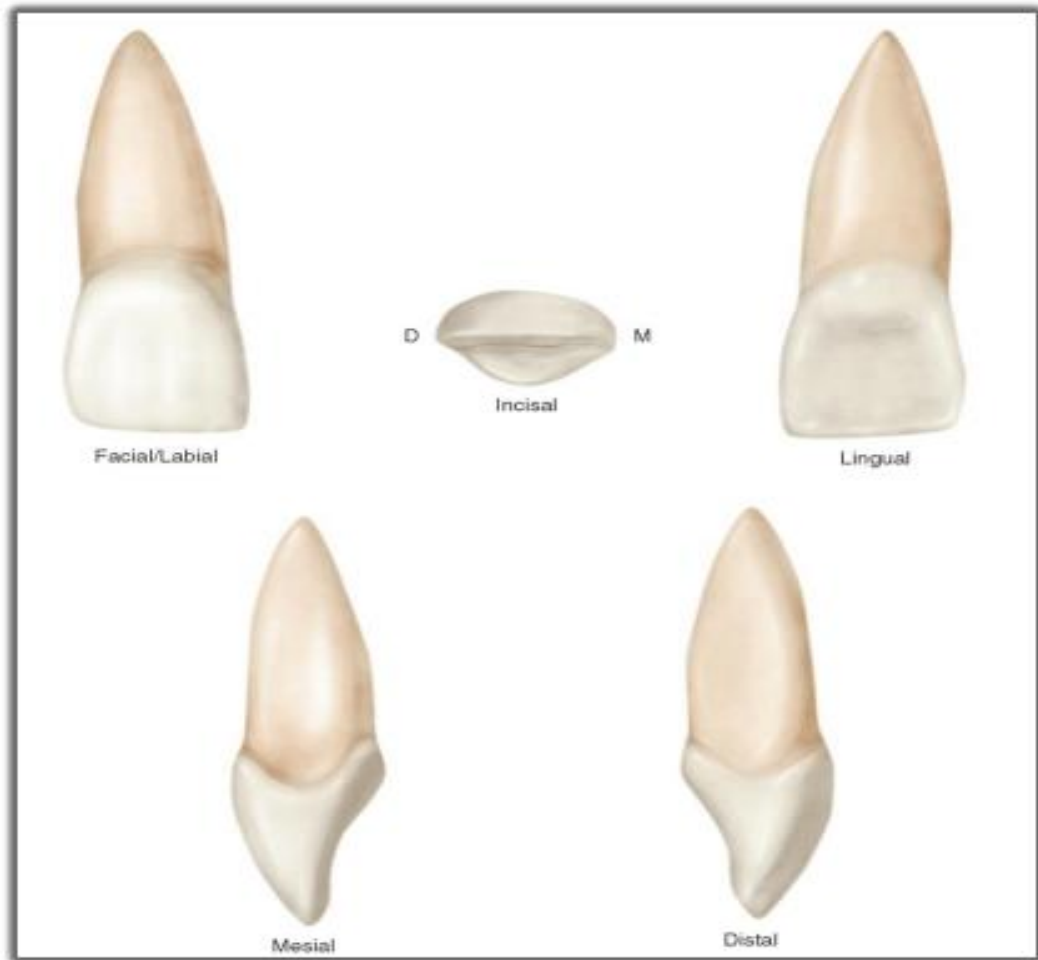
**Distal Aspect**

**There is little difference between distal and mesial outlines. The curvature of the cervical line is less distally than mesially.**

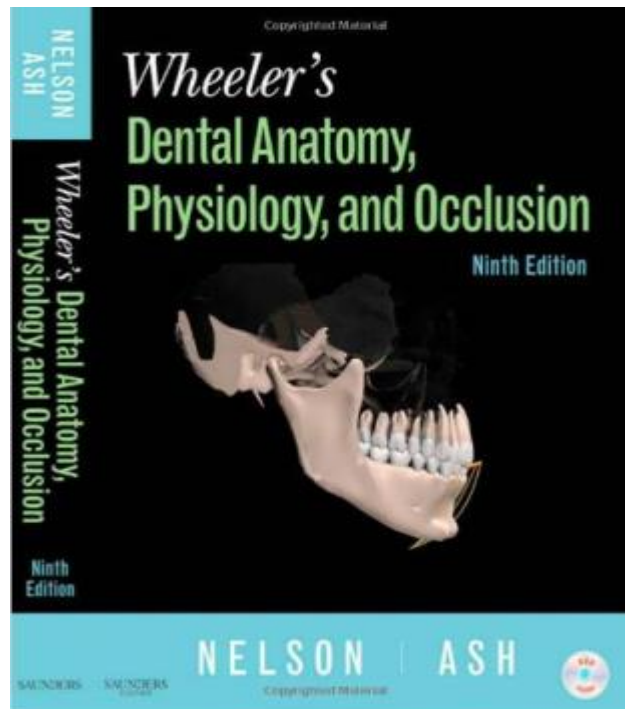
**Incisal Aspect**

- 1. The incisal edge is centered over the root.**
- 2. The labial outline of the crown is broad and flat.**
- 3. The outline of the lingual part tapers lingually to the cingulum.**
- 4. The incisal edge and incisal ridge are well defined.**
- 5. The mesio-distal dimension labially is greater than that lingually.**
- 6. The crown has triangular shape, as the root shape in cross-section.**





**For further reading you can read this book**





# Dental Anatomy

## Lec.5

### **Maxillary lateral incisors**

Maxillary lateral incisors mimics the maxillary central incisor in function, form and anatomy, but is usually smaller in all dimensions except the root length.

#### Principles identifying features of maxillary lateral incisor

- 1.The crown is more rounded, shorter and narrower mesio-distally than the maxillary central incisor.
- 2.The mesio-incisal angle is acute and the disto-incisal angle is more rounded.
- 3.It has a single root with a tapered, distally curved, pointed apex.
- 4.The concavity of lingual fossa is more than that of the maxillary central incisor.

#### Labial Aspect

- 1.The crown is shorter and narrower than that of the maxillary central, but the root is as long as that of the maxillary central incisor or longer.
- 2.The convexity of labial surface of the crown is more than that of the maxillary central incisor.
- 3.The mesial outline resembles that of the maxillary central incisor with more rounded mesio-incisal angle, with the crest of curvature (contact point) located between the middle and incisal third.
- 4.The distal outline is more rounded with crest of curvature (contact point) located at the center of the middle third.
- 5.It has evenly tapered root and curved distally at the apex.
- 6.A line drawn through the center of the root and the crown tends to parallel the mesial outline of the crown and root.

### **Lingual Aspect**

- 1.The mesial and distal marginal ridges and the lingual portion of the incisal ridge are well marked with a more concave lingual fossa.**
- 2.The cingulum is prominent with a tendency toward seeing a deep developmental groove within the lingual fossa.**

### **Mesial Aspect**

- 1. Labiolingually, the crown is narrower than the maxillary central incisor.**
- 2.The curvature of the cervical line is less than that of the maxillary central incisor.**
- 3.The root appears as a tapered cone and a line bisecting the root bisects the incisal ridge which is well developed.**

### **Distal Aspect**

- 1.The curvature of the cervical line distally is less than that of the mesial side.**
- 2.It is not uncommon to find a developmental groove extending to the root.**

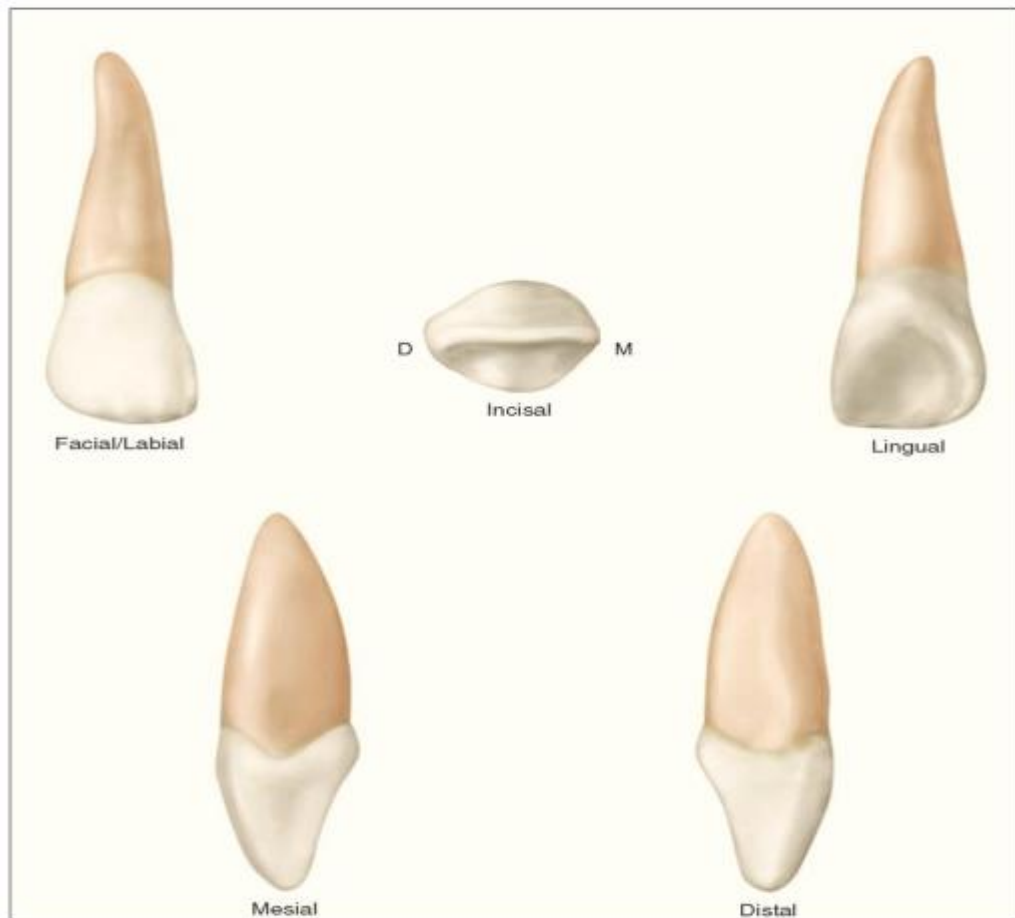
### **Incisal Aspect**

- 1.The incisal aspect resembles that of the maxillary central incisor, but;**
  - (A) The cingulum and incisal ridge may be large.**
  - (B) The labio-lingual to mesio-distal measurement is larger, therefore, it resembles as a small canine.**
- 2.From the incisal aspect, all maxillary lateral incisors reveal more convexity labially and lingually.**

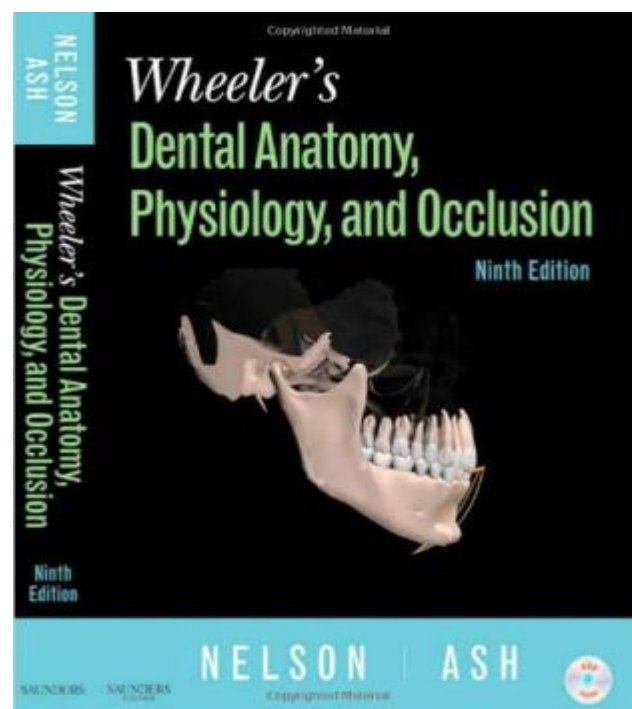
### **Variations from the typical form (Anomalies)**

- 1.Peg-shaped lateral incisor, with a thin root and a small conical crown.**
- 2.The maxillary lateral incisor may be congenitally missing.**

**3. Large developmental groove on the distal aspect extending to the root.**



**For further reading you can read this book**



# Dental Anatomy

## Lec.6

### **PERMANENT MANDIBULAR INCISORS**

Mandibular incisors are four in number which consist of two central and two lateral incisor.

#### **Characteristic features of permanent mandibular incisors:**

- 1.The mandibular incisors have smaller mesiodistal dimensions than any of the other teeth.
- 2.The contact areas are near the incisal ridges mesially and distally.
- 3.The lingual surface is relatively smooth and featureless with the marginal ridges and the cingulum being not well developed.
- 4.The labial surface tilted lingually so that the incisal ridge is lingual to a line bisecting the root.
- 5.The incisal surface of these teeth reveal a labial inclination that is opposite to those of the maxillary incisors which have a lingual inclination.

#### **Principles identifying features of permanent mandibular central incisors**

- 1.It is the smallest tooth in the permanent dentition.
- 2.Single root which is very narrow mesiodistally.
- 3.Well defined distal longitudinal groove is seen on the root.

#### **Labial Aspect**

- 1.The incisal ridge is straight and nearly at a right angle to the long axis of the tooth.
- 2.The distoincisor angle is more rounded than the mesioincisor angle.
- 3.The contact areas are incisal to the junction between incisal and middle thirds of the crown.
- 4.The mesial and distal root outlines are straight with a distally curved apex.

**5.The labial surface of the crown is smooth being flat at the incisal third and becoming more convex as it goes cervically.**

**Lingual Aspect**

- 1.The lingual surface of the crown is smooth with very slight concavity at the incisal third.**
- 2.No developmental grooves are found near the cingulum.**

**Mesial Aspect**

- 1.The labial outline above the cervical curvature is straight.**
- 2.The lingual outline show a shallow concavity ending to the blunt incisal ridge which is lingual to a line bisecting the root.**
- 3.The curvature of the cervical line goes incisally about one third the length of the crown.**
- 4.The mesial surface of the root showed a broad developmental depression for most of the root and this become deeper at the junction of the middle and apical third.**

**Distal Aspect**

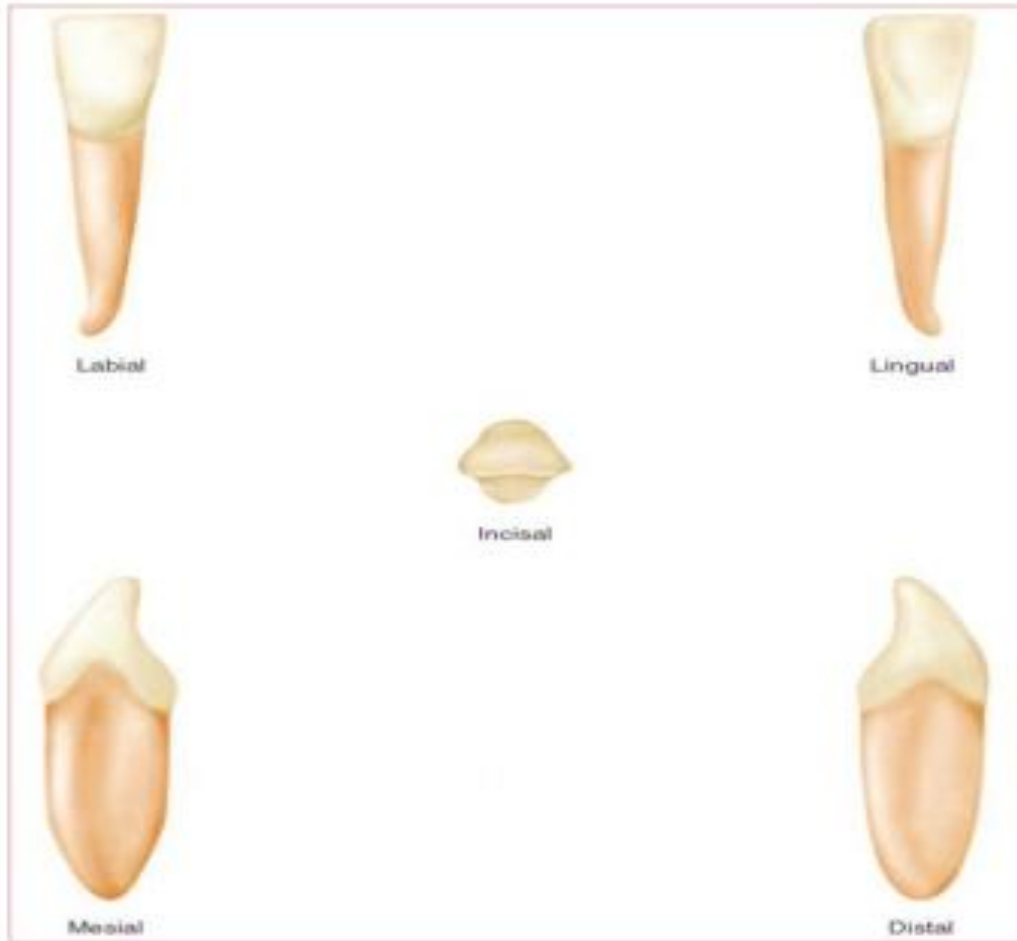
- 1.The cervical line curvature is less than that mesially.**
- 2.The developmental depression in the root is more marked than that on the mesial side with a deeper and more well defined developmental groove in its center.**

**Incisal Aspect**

- 1.The mesial half of the crown is almost identical to the distal half (bilateral symmetry).**
- 2.The incisal edge is at right angle to a line bisecting the crown labiolingually.**
- 3.At the incisal third the labial surface of the crown is broad and flat while in the cervical third slightly convex while the lingual surface is slightly concave at the incisal third.**

4. More of the labial surface may be seen than of the lingual surface from this aspect.

5. Labiolingual diameter is greater than mesiodistal one.



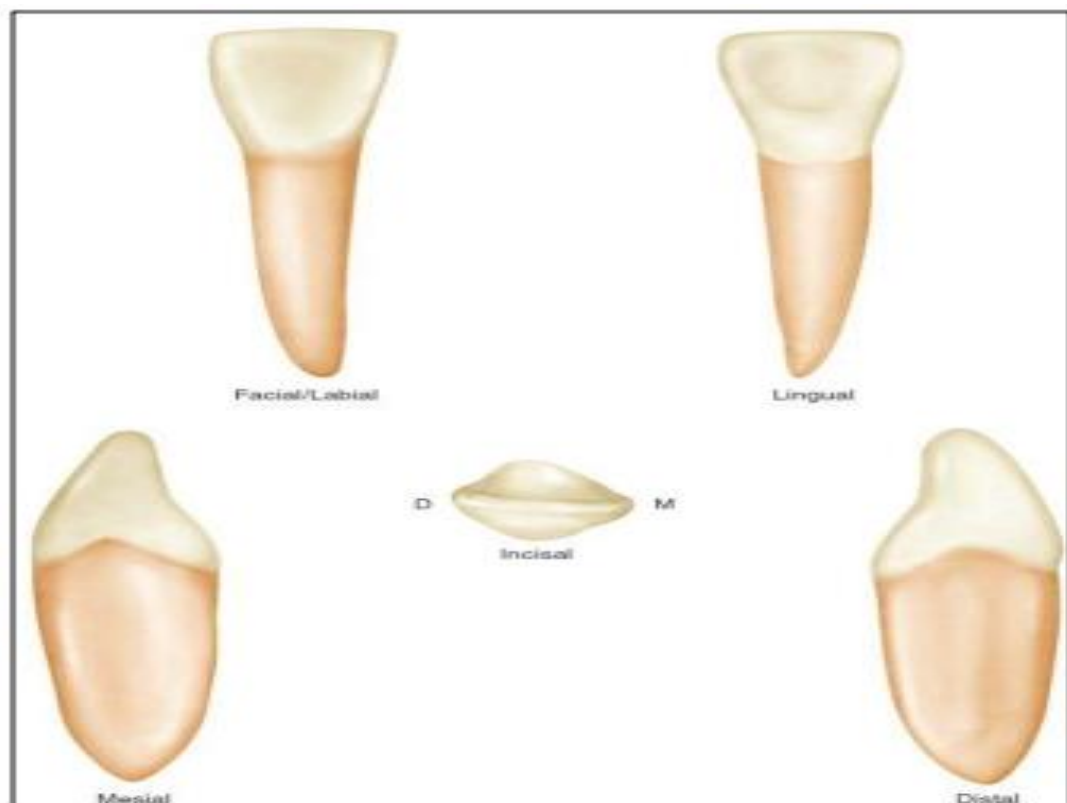
**Figure (1):**Permanent mandibular central incisor.



# **MANDIBULAR LATERAL INCISOR**

## **Principles identifying features of permanent mandibular lateral incisors**

- 1.Slightly larger than mandibular central incisors .
- 2.The crown is slightly longer, but the root is considerably longer than the mandibular central incisors.
- 3.The mesial side of the crown is longer than the distal side, causing the incisal ridge to slope downward in a distal direction.
- 4.The distal contact area is more toward the cervical area than the mesial contact area.
- 5.Faint marginal ridges but more prominent than that in mandibular central incisors.
- 6.The incisal edge is twisted distally in a lingual direction to follow the curvature of the lower arch.
- 7.There are mesial and distal developmental depressions on the root.



**Figure (2):**Permanent mandibular lateral incisor.

# **PERMANENT MAXILLARY CANINES**

## **Characteristic features of permanent canines:**

1. The positions and forms of the canines and their anchorage in the bone have a cosmetic value. Canines are placed at the corners of the mouth which help in keeping normal facial expressions .

2. The canines are the longest and strongest teeth in the mouth.

3. The canines are the most stable teeth in the mouth because of the followings:

\*They have large labiolingual dimension.

\*They have long roots, which are well anchored in the alveolar bone.

\*The crown shape of the canine promotes cleanliness "self-cleansing" so they stay for longer time.

5. The middle labial lobe is highly developed incisally into a strong well-formed cusp.

## **Permanent maxillary canine**

### **Principle identifying features of the permanent maxillary canine:**

1. Single pointed cusp.

2. The distal slope of the cusp is longer than the mesial slope.

3. Marked convex labial outline and bulky palatal cingulum.

4. Very long single root.

### **Labial Aspect**

1. The mesial outline of the crown is convex from the cervical line to the crest of curvature which is located at the junction of the incisal and middle thirds.

2. The distal outline of the crown is slightly concave from the cervical line to the crest of curvature which is located at the center of the middle third.

3. The tip of the cusp is in a line with the center of the root.

4. The distal slope of the cusp is longer than the mesial slope.
5. The cervical line is convex toward the root.
6. The labial surface is smooth except for a shallow depression mesially and distally, dividing the three lobes with the middle one much more developed producing the labial ridge.
7. The root is long and conical with the apex curved distally.

### **Lingual Aspect**

1. The tooth is narrower lingually than labially ( tapered lingually).
2. The cingulum in the maxillary canine is larger than that in the maxillary central and lateral incisors.
3. There is a well-developed lingual ridge confluent with the cusp tip, which divides the lingual fossa into two fossae.
4. There is a developmental depression mesially and distally extending for most of the root length.

### **Mesial Aspect**

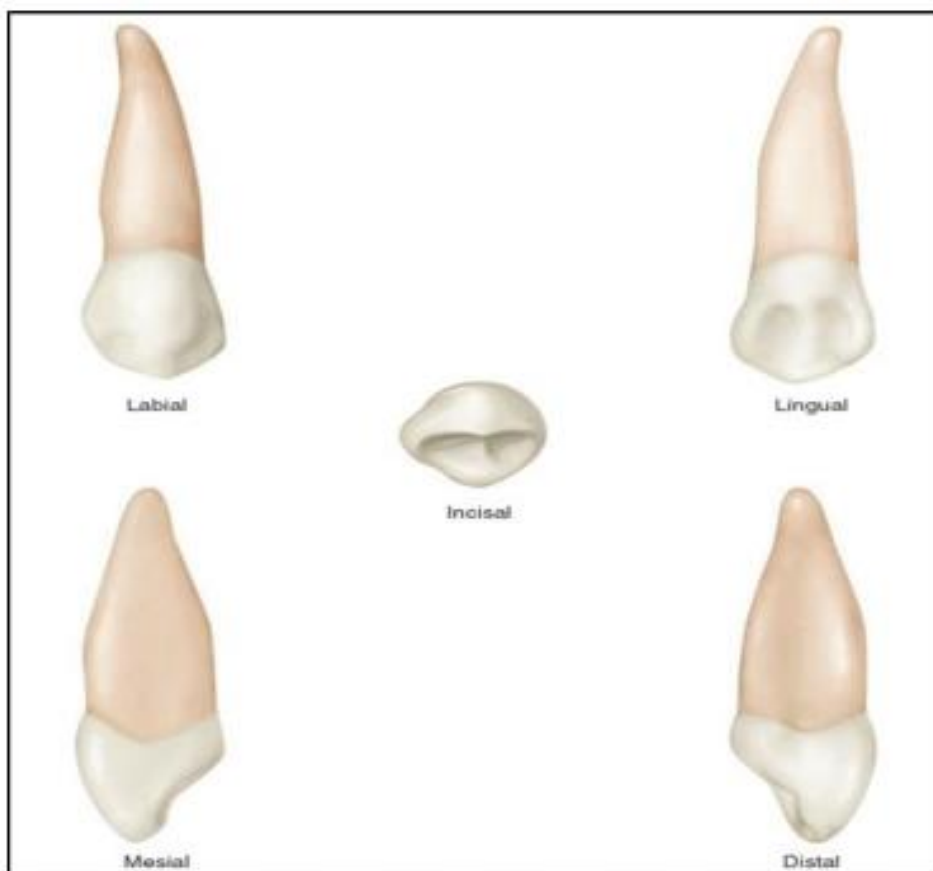
1. The labial and lingual outlines of the crown are more convex than that in the maxillary central and lateral incisors with the crest of curvature (labially and lingually) located at the cervical thirds.
2. The curvature of the cervical line is 2.5 mm toward the cusp.
3. A line bisecting the cusp is labial to a line bisecting the root.
4. There is a developmental depression extending on part of the root.

### **Distal Aspect**

1. The curvature of the cervical line is less distally than mesially (as in the maxillary central and lateral incisors).
2. The developmental depression of the root is more pronounced distally than mesially.

### **Incisal Aspect**

- 1.The labiolingual dimension is greater than the mesiodistal dimension.**
- 2.The ridge of the labial lobe is very noticeable labially with its greatest convexity at the cervical third.**
- 3.The cingulum is well developed and makes a small arc when compared with the labial outline which makes a large arc.**
- 4.The tip of the cusp is labial to center labiolingually and at or slightly mesial to the center mesiodistally.**

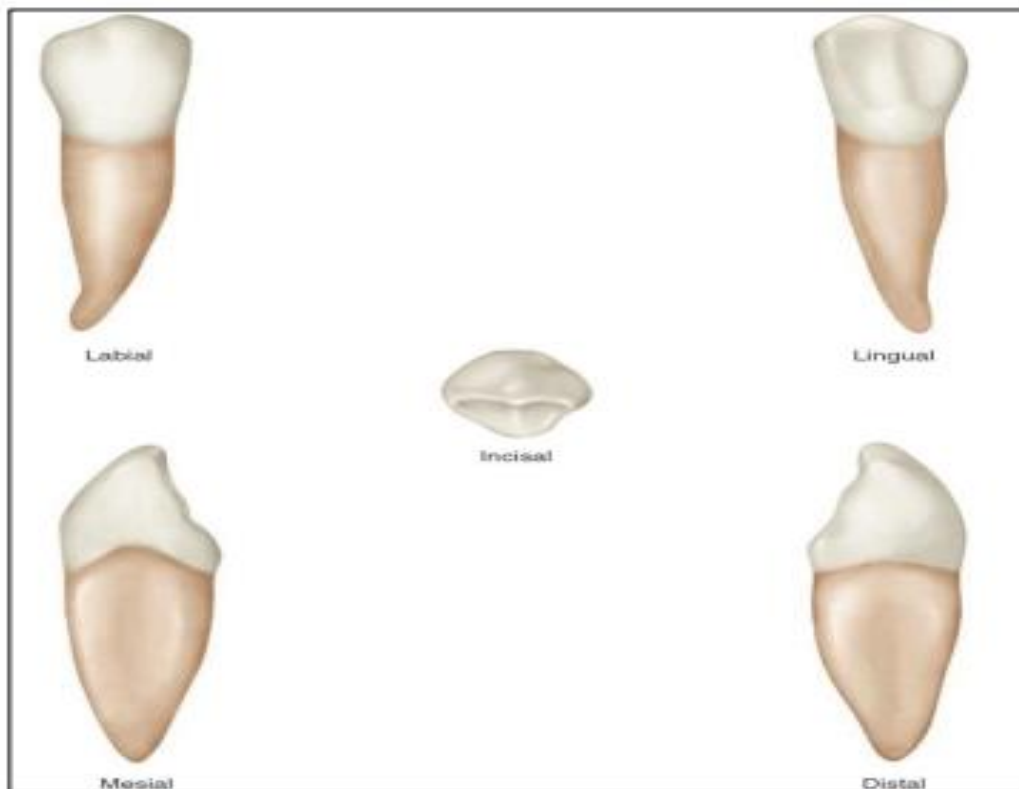


**Figure (3):** Permanent maxillary canine

## **Permanent mandibular canine**

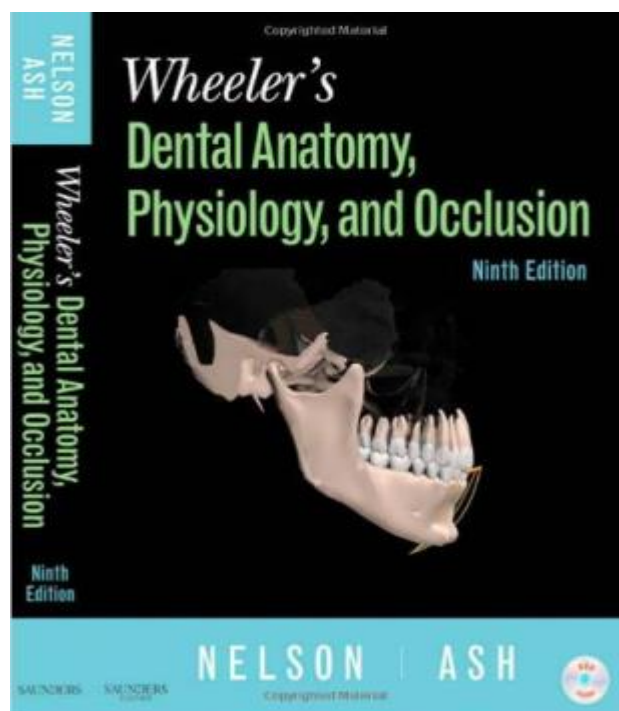
### **Principle identifying features of the permanent mandibular canine:**

- 1.The mandibular canine is narrower mesiodistally and labiolingually than the maxillary canine.**
- 2.Labially the crown of the mandibular canine appears longer.**
- 3.The lingual surface of the crown of the mandibular canine is shorter than that of the maxillary canine, with less developed cingulum and less prominent marginal ridge.**
- 4.The cusp of the mandibular canine is not as well developed as that of the maxillary canine.**
- 5.The tip of the cusp is not in a line with the center of the root.**
- 6.The mesial slope of the cusp is shorter than the distal slope.**
- 7.The distal outline of the crown is more rounded than the mesial outline.**
- 8.The mesial surface of the crown is nearly straight with the mesial surface of the root, with the contact area being near the mesioincisal angle.**
- 9.The distal contact area is located more incisally than the maxillary canine.**
- 10.The mandibular canine root is shorter by 1 or 2 mm on average than that of the maxillary canine.**



**Figure (4):** Permanent mandibular canine

**For further reading you can read this book**



# Dental Anatomy

## Lec.7

### **PERMANENT MAXILLARY PREMOLARS**

Maxillary premolars are four in number: two in the right and two in the left. They are posterior to the canines and anterior to the molars. The maxillary premolars have shorter crowns and shorter roots than those of the maxillary canines. The maxillary first premolar is larger than the maxillary second premolar. Premolars are named so because they are anterior to molars in a permanent dentition. They succeed the deciduous molars (there are no premolars in deciduous dentition). They are also called bicuspid (having two cusps), but this name is not widely used because the mandibular first premolar has one functional cusp.

The premolars are intermediate between molars and canines in ***Form:*** The labial aspect of the canine and the buccal aspect of premolar are similar.

***Function:*** The canine is used to tear food while the premolars and molars are used to grind it.

***Position :*** The premolars are in the center of the dental arch.

#### ***Some characteristic features of all posterior teeth***

1. Greater relative facio-lingual measurement as compared with the mesio-distal measurement.
2. Broader contact areas.
3. Contact areas nearly at the same level.
4. Less curvature of the cervical line mesially and distally.
5. Shorter crown cervico-occlusally when compared with anterior teeth.

## **MAXILLARY FIRST PREMOLAR**

### **Principle identifying features:**

- 1. Two sharply defined cusps, buccal (1mm) longer than the lingual.**
- 2. Mesial slope of the buccal cusp is longer than the distal slope.**
- 3. Two roots ; buccal and palatal and the bifurcation is at the middle third of the root.**
- 4. Developmental depression on the mesial surface of the crown extending to the root.**
- 5. Central developmental groove interrupts the mesial marginal ridge.**

### **Buccal Aspect**

From this aspect the crown is roughly trapezoidal in shape.

- 1. The mesial outline is slightly concave from the cervical line to the relatively broad curvature of the contact area.**
- 2. The crest of curvature of the mesial contact area is immediately occlusal to the center of the middle third.**
- 3. The distal outline of the crown is straighter than that mesially.**
- 4. The distal contact area has a broader curvature than that found mesially with its position slightly more occlusally. In spite of that, the contact areas are nearly at the same level with each other.**
- 5. The mesial slope of the cusp is straight and longer than the distal slope, which is shorter.**
- 6. The buccal surface of the crown is convex showing a strongly developed middle buccal lobe. The ridge which is continuous from the tip of the cusp to the cervical line is called the buccal ridge.**

### **Lingual Aspect**

- 1. The crown tapers toward the lingual because the lingual cusp is narrower than the buccal cusp.**
- 2. The lingual cusp is smooth and spheroidal. The cusp tip is pointed with mesial and distal slopes meeting at (90 degree) angle.**
- 3. The mesial and distal outlines lingually are convex being continuous with the slopes of the lingual cusp.**
- 4. The lingual cusp is shorter than the buccal cusp.**
- 5. The apex of the lingual root of a two rooted tooth is more blunt than the buccal one.**



### Mesial Aspect

1. The crown is roughly trapezoidal, with the longest uneven side is toward the cervical line, and the shortest is toward the occlusal portion.
2. The tips of the cusps are well within the confines of the root trunk.
3. The cervical line has less curvature (1mm) than any anterior tooth.
4. The buccal outline is convex and the crest of curvature is within the cervical third (near the junction between the cervical and middle thirds) and then become less convex till the cusp tip.
5. The lingual outline is convex and the crest of curvature is within the middle third (near the center of the middle third).
6. The mesial marginal ridge is at the level of the junction of the middle and occlusal thirds and is crossed by the mesial developmental groove.
7. The root is bifurcated for half of its total length.
8. The mesial developmental depression start from the contact area to the bifurcation area.

### Distal Aspect

1. The curvature of the cervical line distally is less than that of the mesial side.
2. There is no developmental groove crossing the distal marginal ridge.
3. There is no developmental depression.

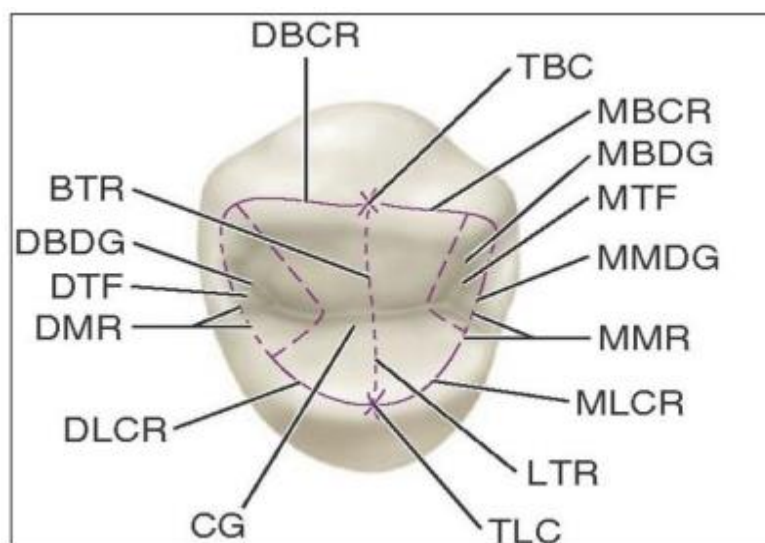
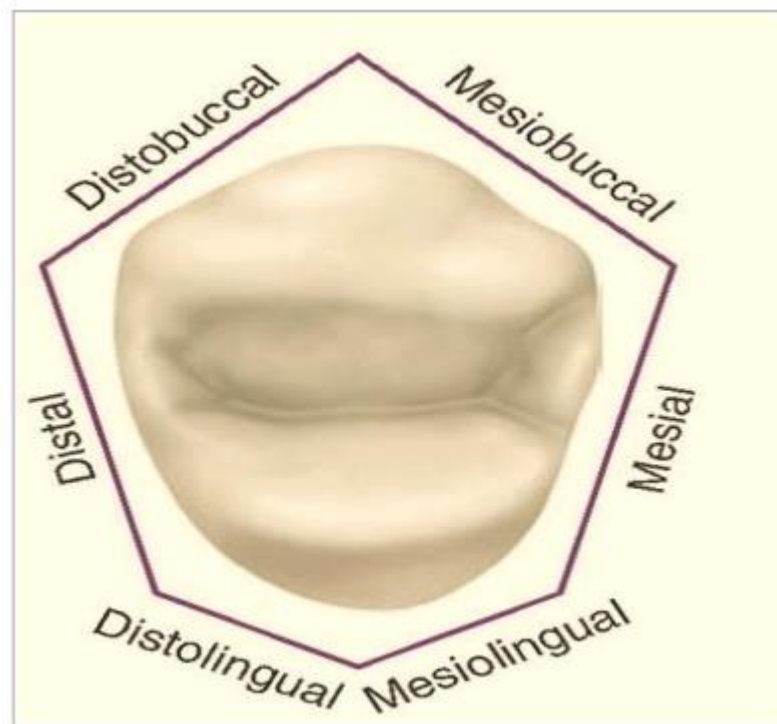
### Occlusal Aspect

1. It resemble an unequal hexagon ( six-sided figure): the buccal sides are equal, the mesial sides is shorter than the distal side and the mesio-lingual side is shorter than the disto-lingual side.
2. The distal crest of curvature is buccal to the mesial crest of curvature.
3. The bucco-lingual dimension is much greater than the mesio-distal dimension.
4. The occlusal surface is circumscribed by the cusps and marginal ridges.
5. A central developmental groove divides the crown into buccal and lingual parts. It extends from near the distal marginal ridge to the mesial marginal ridge where it joins the mesial marginal

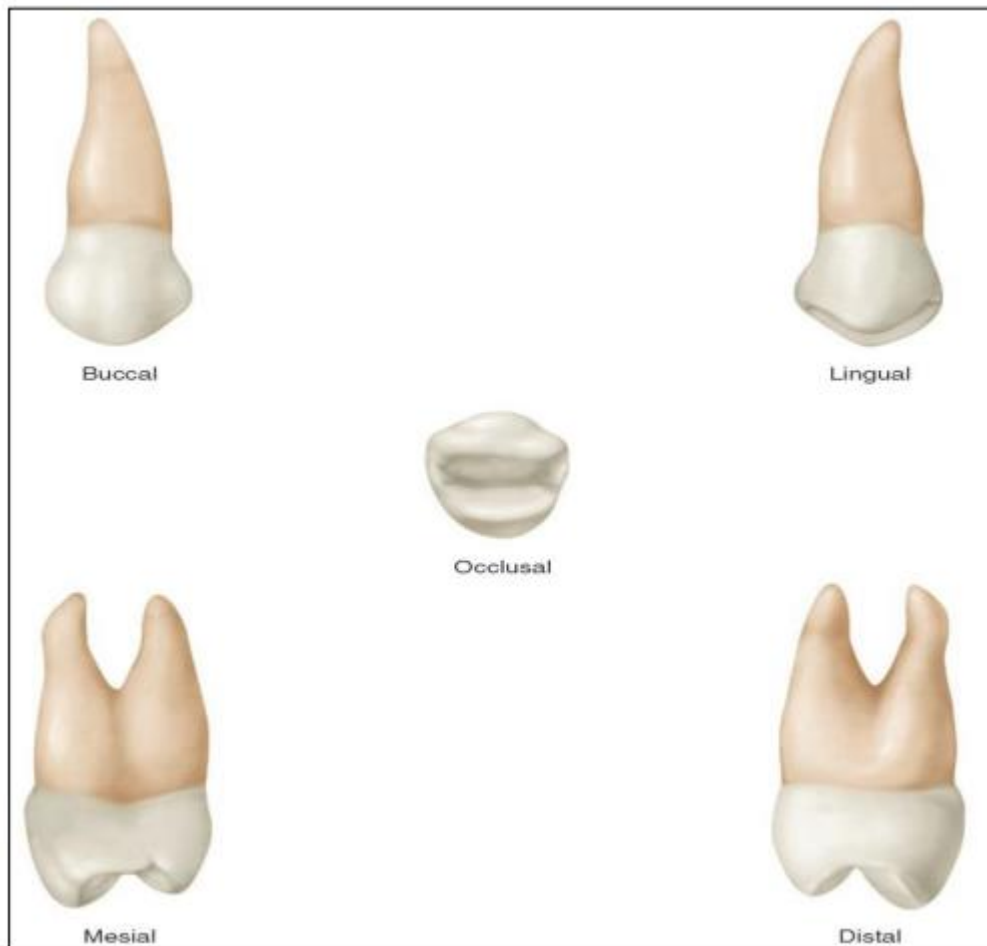
developmental groove.

6. In the mesial and distal triangular fossae, there are two developmental grooves (mesio-buccal and disto-buccal grooves respectively) that join the central groove. The junctions of these grooves make the developmental pits (mesial and distal developmental pits respectively).

7. The lingual cusp is sharper and more pointed than the buccal cusp.



Occlusal aspect. **TBC**, Tip of buccal cusp. **MBCR**, mesiobuccal cusp ridge. **MBDG**, Mesiobuccal developmental groove. **MTF**, mesial triangular fossa. **MMDG**, mesial marginal developmental groove; **MMR**, mesial marginal ridge. **MLCR**, mesiolingual cusp ridge. **LTR**, lingual triangular ridge. **TLC**, tip of lingual cusp. **CG**, central groove. **DLCR**, distolingual cusp ridge. **DMR**, distal marginal ridge. **DTF**, distal triangular fossa; **DBDG**, distobuccal developmental groove. **BTR**, buccal triangular ridge. **DBCR**, distobuccal cusp ridge.

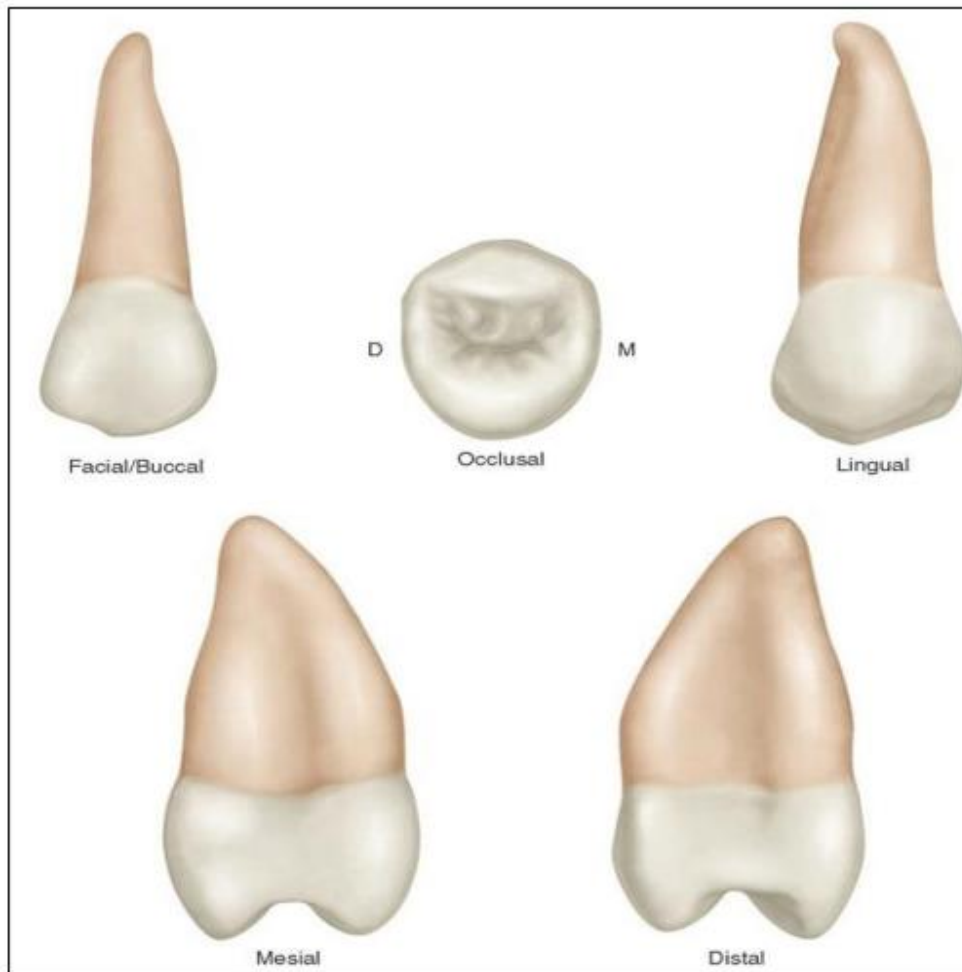


## **MAXILLARY SECOND PREMOLAR**

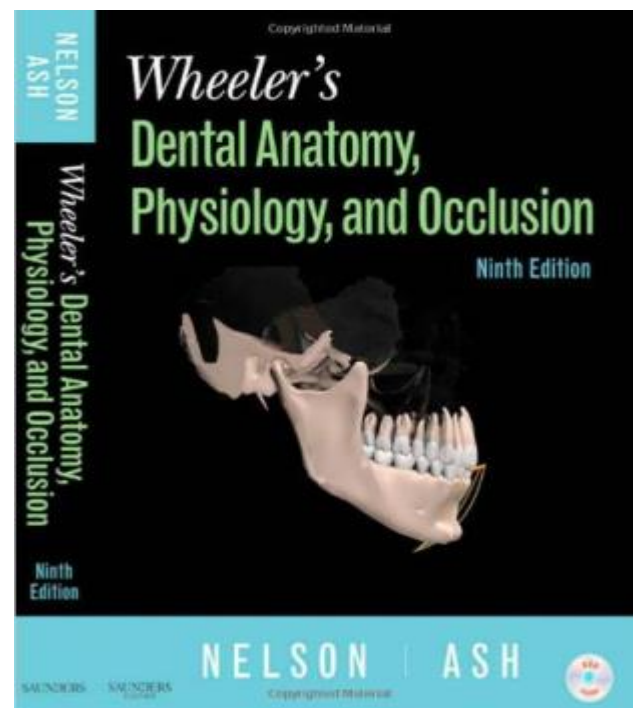
### **Principle identifying features:**

- 1. The buccal and lingual cusps are equal in height.**
- 2. The mesial slope of the buccal cusp is shorter than the distal slope.**
- 3. The mesial surface has no developmental depression.**
- 4. Has a single root.**
- 5. The occlusal surface is more rounded or oval.**
- 6. The central developmental groove is shorter and more irregular**

with more supplemental grooves on the occlusal surface.  
7. There is no mesial groove crossing the mesial marginal ridge.



For further reading you can read this book



# Dental Anatomy

## Lec.8

### **PERMANENT MANDIBULAR PREMOLARS**

#### Mandibular first premolar

It is the smaller of the two mandibular premolars. It resembles both the mandibular canine and the mandibular second premolar in function and has some of the characteristic features of them.

#### Characteristic features of permanent mandibular first premolar that resemble those of the mandibular canine:

- 1.The buccal cusp is long, sharp and is the only occluding cusp.
- 2.The bucco-lingual measurement is similar to that of the mandibular canine.
- 3.The occlusal surface slopes sharply lingually in a cervical direction.
- 4.The mesio-buccal cusp ridge is shorter than the disto-buccal cusp ridge.
- 5.The outline form from the occlusal aspect resembles the incisal aspect of the mandibular canine.

#### Characteristic features of permanent mandibular first premolar that resemble those of the mandibular second premolar:

- 1.The mesial and distal contact areas are located nearly at the same level.
- 2.The curvature of the cervical line mesially and distally is

similar.

**3.The tooth has more than one cusp.**

**4.The length of the root of the mandibular first premolar is closer to the length of the root of the mandibular second premolar.**

**Principle identifying features:**

**1.Marked lingual inclination of the crown.**

**2.Two cusps; buccal and lingual; the buccal cusp is larger and the lingual cusp is like a more developed cingulum.**

**3.Circular occlusal outline.**

**4.Single rounded root.**

**Buccal Aspect:**

**1.The crown is roughly trapezoidal with a prominent middle buccal ridge, which continuous from the cusp tip to the cervical line.**

**2.The mesial slope of the buccal cusp is shorter than the distal slope.**

**3.The contact areas mesially and distally are broad and at the same level.**

**4.The mesial and distal outlines from the cervical line to the crest of curvature are slightly concave.**

**5.The tip of the buccal cusp is sharp and located little mesial to the long axis of the crown.**

### **Lingual Aspect:**

- 1.The crown and the root taper lingually and the occlusal surface inclines greatly cervically.**
- 2.The lingual cusp is poorly developed but is pointed.**
- 3.There is a developmental groove named mesio-lingual developmental groove, which acts as a line of demarcation between the mesio-buccal lobe and the lingual lobe and extend into the mesial fossa of the occlusal surface.**

### **Mesial Aspect:**

- 1.The tip of the buccal cusp nearly centered over the root and the convexity of the lingual outline of the cusp will be lingual to the outline of the root .**
- 2.The buccal outline is very curved and the crest of curvature is near the middle third of the crown.**
- 3.The lingual outline is less curved than the buccal outline, with the crest of curvature at the center of the middle third.**
- 4.The height of the lingual cusp is two-thirds the height of the buccal cusp from the cervical line to the tip of the cusp.**
- 5.The surface of the crown mesially is smooth except for the presence of the mesio-lingual developmental groove.**

### **Distal Aspect:**

**The distal aspect of the mandibular first premolar differs from the mesial aspect in the following points:**

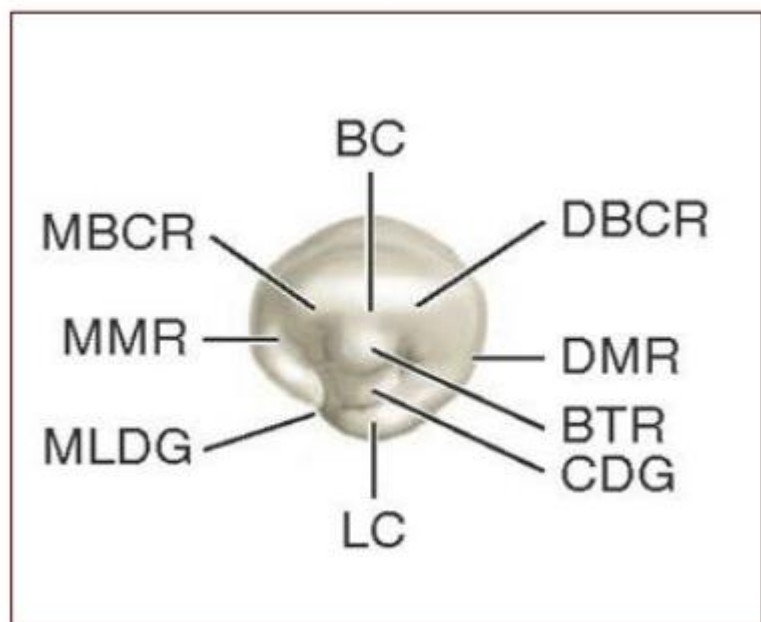
- 1.There is no developmental groove in the distal aspect.**
- 2.The distal marginal ridge is higher than the mesial marginal ridge with less inclination lingually.**
- 3.The surface of the root distally exhibits more convexity than was**

found mesially. Shallow developmental depression is presented on the root.

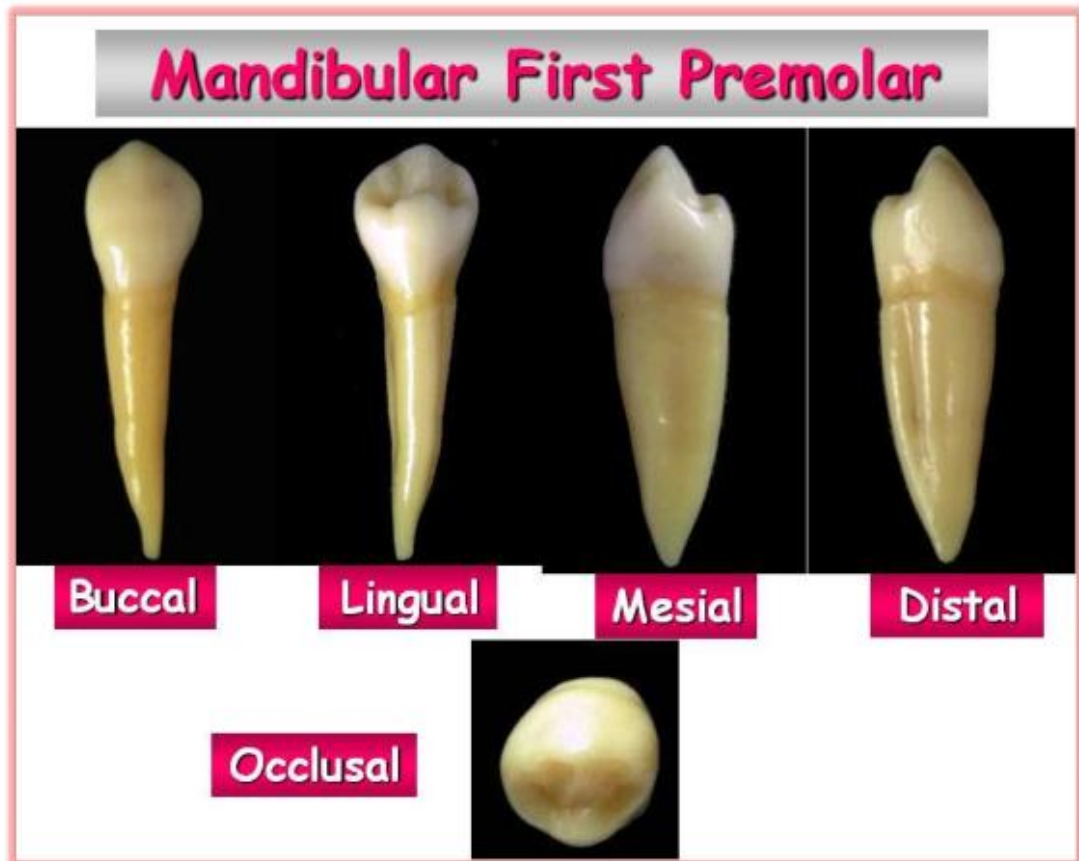**Occlusal Aspect:**

- 1.The buccal ridge is prominent.
- 2.The mesio-buccal and the disto-buccal line angles are rounded and prominent.
- 3.The crown converges sharply to the center of the lingual surface.
- 4.The marginal ridges are well developed .
- 5.The lingual cusp is small.
- 6.The triangular ridge of the buccal cusp is large , while the triangular ridge of the lingual cusp is small.
- 7.There are two fossae; mesial and distal triangular fossae.
- 8.The mesial contact area is smaller than the distal contact area because it is constricted by the mesio-lingual developmental groove.

BC, Buccal cusp; BTR, buccal triangular ridge; LC, lingual cusp; MLDG, mesiolingual developmental groove; CL, cervical line; MMR, mesial marginal ridge; DBCR, distobuccal cusp ridge; DMR, distal marginal ridge; CDG, central developmental groove; MBCR, mesiobuccal cusp ridge.



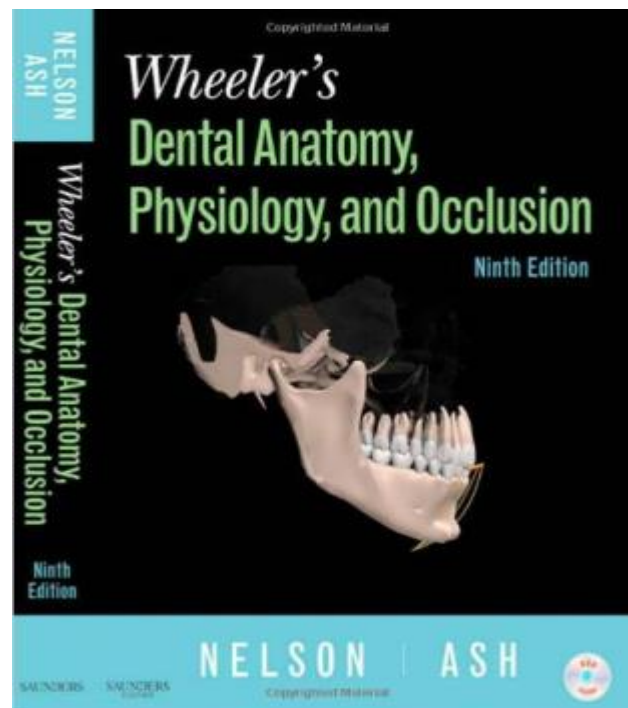




**Figure (1):**Permanent mandibular first premolar.

**For further reading you can read this book**

*Wheeler's Dental Anatomy, Physiology, and Occlusion*



# Dental Anatomy

Lecture (8)



---

## **PERMANENT MANDIBULAR PREMOLARS**

### **Mandibular first premolar**

It is the smaller of the two mandibular premolars. It resembles both the mandibular canine and the mandibular second premolar in function and has some of the characteristic features of them.

#### **Characteristic features of permanent mandibular first premolar that resemble those of the mandibular canine.**

1. The buccal cusp is long, sharp and is the only occluding cusp.
2. The bucco-lingual measurement is similar to that of the mandibular canine.
3. The occlusal surface slopes sharply lingually in a cervical direction.
4. The mesio-buccal cusp ridge is shorter than the disto-buccal cusp ridge.
5. The outline form from the occlusal aspect resembles the incisal aspect of the mandibular canine.

#### **Characteristic features of permanent mandibular first premolar that resemble those of the mandibular second premolar.**

1. The mesial and distal contact areas are located nearly at the same level.
2. The curvature of the cervical line mesially and distally is similar.
3. The tooth has more than one cusp.
4. The length of the root of the mandibular first premolar is closer to the length of the root of the mandibular second premolar.

### **Principle identifying features**

1. Marked lingual inclination of the crown.
2. Two cusps; buccal and lingual; the buccal cusp is larger and the lingual cusp is like a more developed cingulum.
3. Circular occlusal outline.
4. Single rounded root.

### **Buccal Aspect**

1. The crown is roughly trapezoidal with a prominent middle buccal ridge, which continuous from the cusp tip to the cervical line.
2. The mesial slope of the buccal cusp is shorter than the distal slope.
3. The contact areas mesially and distally are broad and at the same level.
4. The mesial and distal outlines from the cervical line to the crest of curvature are slightly concave.
5. The tip of the buccal cusp is sharp and located little mesial to the long axis of the crown.

### **Lingual Aspect**

1. The crown and the root taper lingually and the occlusal surface inclines greatly cervically.
2. The lingual cusp is poorly developed but is pointed.
3. There is a developmental groove named mesio-lingual developmental groove, which acts as a line of demarcation between the mesio-buccal lobe and the lingual lobe and extend into the mesial fossa of the occlusal surface.

### **Mesial Aspect**

1. The tip of the buccal cusp nearly centered over the root and the convexity of the lingual outline of the cusp will be lingual to the outline of the root .
2. The buccal outline is very curved and the crest of curvature is near the middle third of the crown.

3. The lingual outline is less curved than the buccal outline, with the crest of curvature at the center of the middle third.
4. The height of the lingual cusp is two-thirds the height of the buccal cusp from the cervical line to the tip of the cusp.
5. The surface of the crown mesially is smooth except for the presence of the mesio-lingual developmental groove.

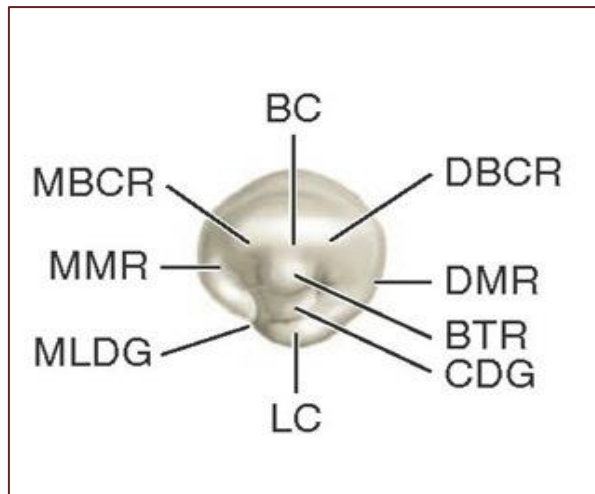
### **Distal Aspect**

**The distal aspect of the mandibular first premolar differs from the mesial aspect in the following points:**

1. There is no developmental groove in the distal aspect.
2. The distal marginal ridge is higher than the mesial marginal ridge with less inclination lingually.
3. The surface of the root distally exhibits more convexity than was found mesially. Shallow developmental depression is presented on the root.

### **Occlusal Aspect**

1. The buccal ridge is prominent.
2. The mesio-buccal and the disto-buccal line angles are rounded and prominent.
3. The crown converges sharply to the center of the lingual surface.
4. The marginal ridges are well developed .
5. The lingual cusp is small.
6. The triangular ridge of the buccal cusp is large , while the triangular ridge of the lingual cusp is small.
7. There are two fossae; mesial and distal triangular fossae.
8. The mesial contact area is smaller than the distal contact area because it is constricted by the mesio-lingual developmental groove.



BC, Buccal cusp; BTR, buccal triangular ridge; LC, lingual cusp; MLDG, mesiolingual developmental groove; CL, cervical line; MMR, mesial marginal ridge; DBCR, distobuccal cusp ridge; DMR, distal marginal ridge; CDG, central developmental groove; MBCR, mesiobuccal cusp ridge.

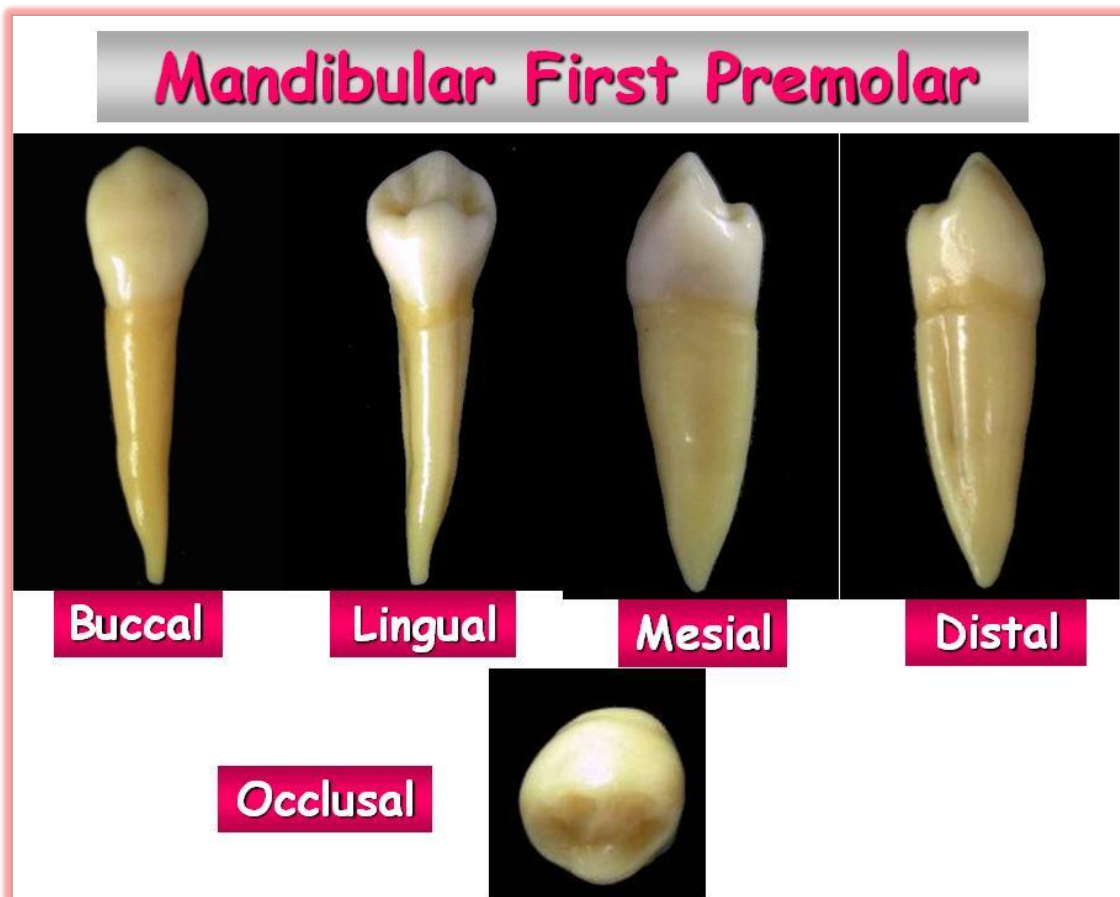


Figure (1):Permanent mandibular first premolar.

# Dental Anatomy



Lecture (9)

---

## **PERMANENT MANDIBULAR SECOND PREMOLARS**

### **Principle identifying features**

1. It is larger than the mandibular first premolars.
2. The cusps are more equal in with less pointed tips. Usually this tooth has three cusps, one buccal and two lingual ; or may have only two cusps, one buccal and one lingual.
3. The occlusal outline is almost square in appearance with no mesio-lingual developmental groove.

### **Buccal Aspect**

1. The buccal cusp is shorter and less pointed than that of mandibular first premolar.
2. The contact areas are broad and high (appear to be higher because of the shorter buccal cusp).
3. The root is broader mesio-distally than that of mandibular first premolar ending with a more blunt apex.

### **Lingual Aspect**

The lingual surface of the crown is smooth and spheroidal.

From this aspect this tooth differs from the mandibular first premolar in :

1. The lingual cusps are more developed (longer cusps).
2. The less occlusal surface may be seen from this aspect. However because the lingual cusps are slightly shorter than the buccal cusp, part of the buccal portion of the occlusal surface may be seen.

**3.A.In the three cusps type:** There are two lingual cusps, the mesio-lingual is larger than the disto-lingual cusp and are divided by the lingual developmental groove.

**B.In the two cusps type:** There is a large cusp of the same height as in the three cusps type. There is a developmental depression distolingually where the lingual cusp ridge joins the distal marginal ridge.

### **Mesial Aspect**

**From this aspect, this tooth differs from the mandibular first premolar in:**

- 1.The crown and root are wider buccolingually.
- 2.The buccal cusp is not nearly centered over the root trunk and it is shorter .
- 3.The marginal ridge is at a right angle to the long axis of the tooth with less occlusal surface may be seen.
- 4.There is no mesio-lingual developmental groove on the crown.
- 5.The root is longer with more blunt apex.

### **Distal Aspect**

- 1.All three cusps may be seen .
- 2.The distal marginal ridge is lower than that mesially revealing more of the occlusal surface.

### **Occlusal Aspect**

#### **A.Three cusps type:**

- 1.The occlusal aspect is square in shape
- 2.Three cusps: the buccal is the largest, followed by the mesio-lingual cusp, and then the disto-lingual cusp.
- 3.Each cusp has a well-formed triangular ridge separated by deep developmental grooves which form a Y-shaped on the occlusal surface.
- 4.There are a three developmental grooves;

A.Mesial developmental groove travels in a mesiobuccal direction and ends in the mesial triangular fossa just distal to the mesial marginal ridge.

**B.**Distal developmental groove travels in a distobuccal direction, and it is shorter than the mesial groove, ends in the distal triangular fossa mesial to the distal marginal ridge.

**C.**Lingual developmental groove separating the two lingual cusps.

**5.**These grooves converge in a central pit which is placed slightly towards the distal side.

**6.**Supplemental grooves are often seen.

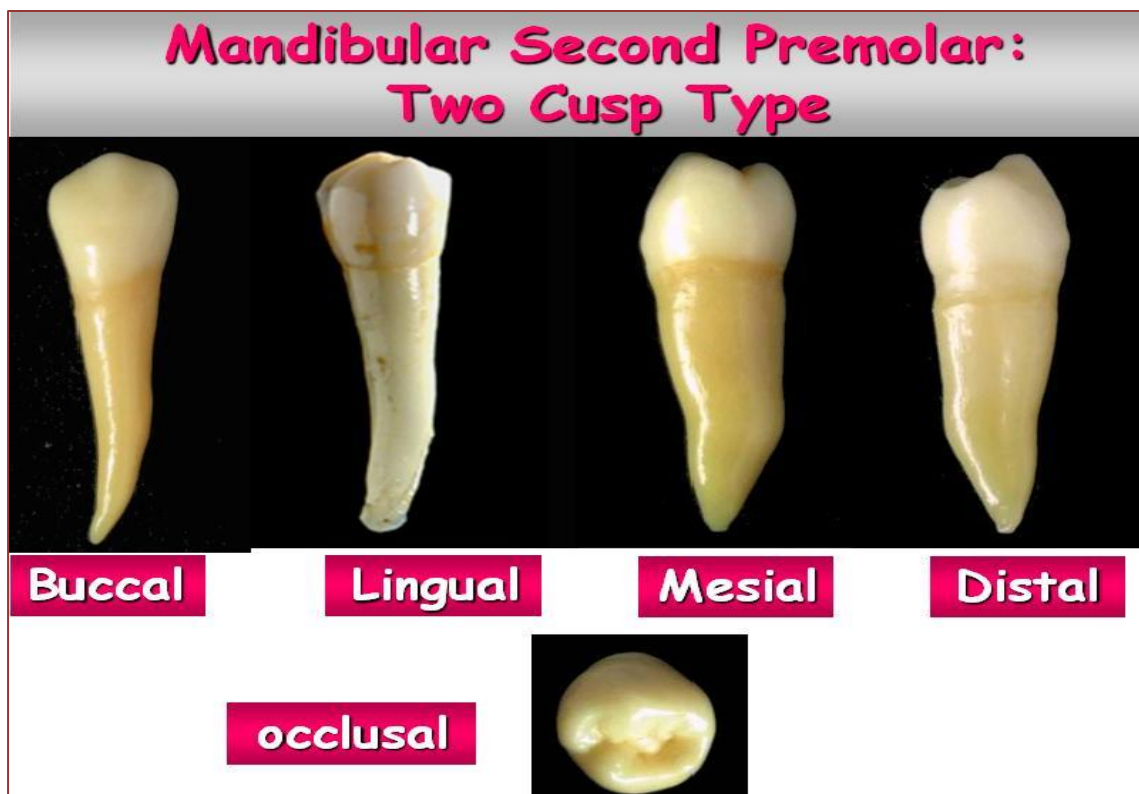**B. Two cusps type:**

**1.** Appear more rounded than the more angular three cusps type.

**2.** There is one well-developed lingual cusp which is large and opposite the buccal cusp.

**3.** A central developmental groove travels in a mesio-distal direction with its terminals centered in the mesial and distal triangular fossae.

Sometimes mesial and distal developmental pits in the centers of these fossae may be seen.



**Figure (1):**Permanent mandibular second premolar.



# Dental Anatomy



Lecture (10)

---

## **PERMANENT MAXILLARY MOLARS**

Permanent maxillary molars are the largest and strongest maxillary teeth. They have three roots; two buccal and one lingual (palatal). They are not succedaneous teeth as they erupt behind the deciduous molars. Their main function is grinding the food and supporting the muscles of mastication.

### **Maxillary first molar**

It is the largest tooth in the maxillary arch.

#### **Principle identifying features**

1. Rhomboidal occlusal outline.
2. The presence of a fifth cusp named (the cusp of Carabelli) a non-functional cusp on the lingual surface of the mesio-lingual cusp.
3. The presence of an oblique ridge extending from the mesio-lingual cusp to the disto-buccal cusp.
4. The presence of three well-separated and well-developed roots; two buccal and one lingual. The lingual root is the longest.

#### **Buccal Aspect**

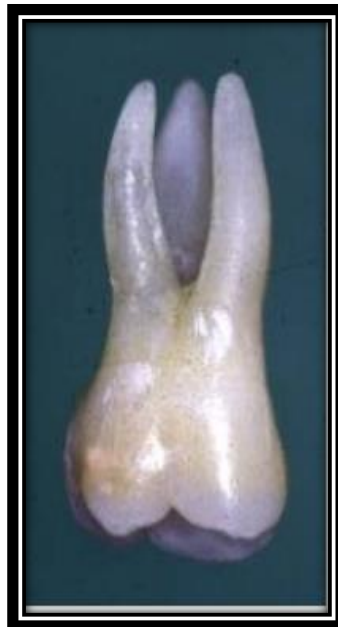1. The crown is roughly trapezoidal and the cervical line shows very little convexity which is directed toward the root.
2. The mesial outline of the crown is straight, curving occlusally as it reaches the contact area which is located at the junction between the occlusal and middle thirds.

3.The distal outline of the crown is convex, with the contact area located at the center of the middle third.

4.The mesio-buccal cusp is broader than the disto-buccal, and its mesial and distal slopes meet at an obtuse angle, while the mesial and distal slopes of the disto-buccal cusp meet at a right angle (which is sharper) and we may see the lingual cusps.

5.The buccal developmental groove divides the two buccal cusps in equal distance and it terminates apically.

6.The three roots are visible and inclined distally, with the lingual root is the longest.



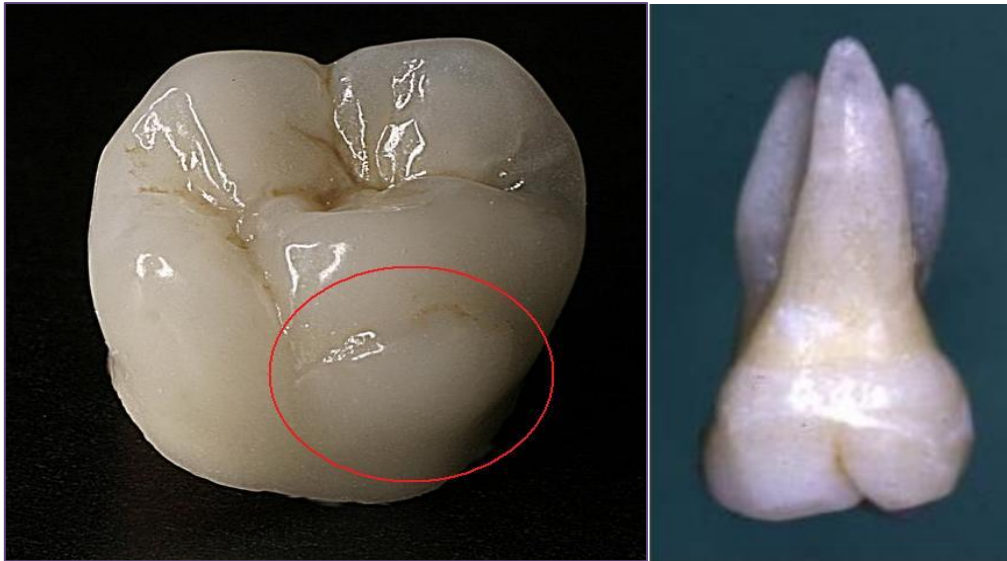
### *Lingual Aspect*

1.The lingual cusps only can be seen, with the mesio-lingual cusp is the largest cusp and accounts for  $\frac{3}{5}$  of the mesio-distal width of the crown ,while the disto-lingual cusp accounts for  $\frac{2}{5}$  of the mesio-distal dimension.

2.The lingual developmental groove starts approximately at the center mesio-distally and curves sharply distally then continues on the occlusal surface.

3.The fifth cusp (the cusp of carabelli) is 1.5 mm cervical to the mesio-lingual cusp tip, and an irregular developmental groove separates this cusp from the mesio-lingual cusp.

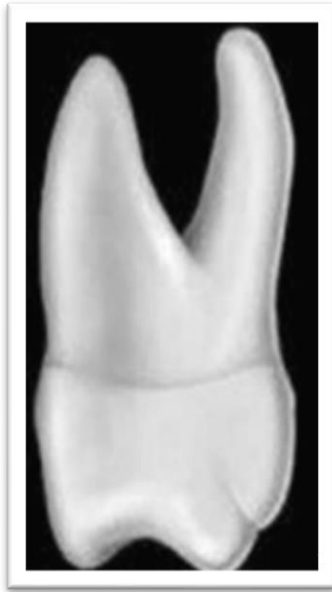4.There are three roots visible, with the lingual root making most of this aspect.



### *Cusp of Carabelli*

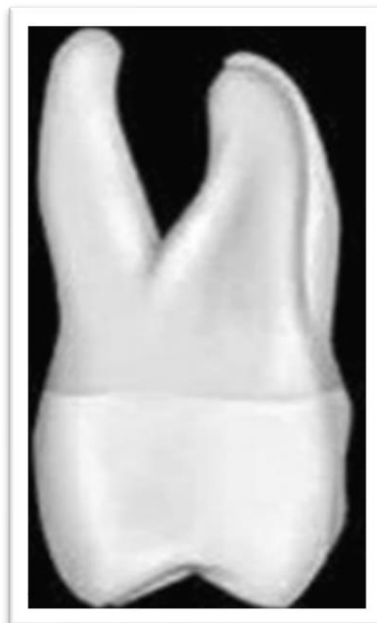#### *Mesial Aspect*

1. The buccal outline has a crest of curvature within the cervical third, then it continues with a convex outline to the tip of the cusp.
2. The lingual outline has a crest of curvature within the middle third, and it shows a convex pattern until it reaches the cusp of Carabelli, at which it shows another convexity.
3. The mesial marginal ridge is located at a level  $\frac{1}{5}$  the height of the crown.
4. The cervical line curves occlusally about 1 mm.
5. The mesial contact area is buccal to the bucco-lingual center of the crown.
6. The lingual and mesio-buccal roots can be seen.



**Distal Aspect**

1. The general outline is similar to that of the mesial aspect, but the bucco-lingual measurement is more mesially than distally .
2. The distal marginal ridge is located more cervically so we can see part of the occlusal surface.
3. The curvature of the cervical line is zero.
4. All the three roots are visible, and the disto-buccal root is the smallest one.



### **Occlusal Aspect**

- 1.The occlusal outline is rhomboidal with the greater bucco-lingual measurement mesially than distally and greater mesio-distal measurement lingually than buccally.
- 2.Four well developed cusps can be seen: the mesio-lingual cusp is the largest then the mesio-buccal, disto-lingual ,disto-buccal then the cusp of Carabelli.
- 3.The mesio-buccal and disto-lingual line angles are acute and the mesio-lingual and disto-buccal line angles are obtuse.
- 4.There is an oblique ridge formed by the union of the triangular ridge of the disto-buccal cusp and the distal ridge of the mesio-lingual cusp crossing the occlusal surface obliquely.

### **5. There are four fossae:**

#### **A. Major fossae**

1. Central fossa: roughly triangular in shape located mesial to the oblique ridge.
2. Distal fossa: located distal to the oblique ridge .

#### **B. Minor fossae:**

1. Mesial triangular fossa: located distal to the mesial marginal ridge.
2. Distal triangular fossa: located mesial to the distal marginal ridge.

### **6. There are six developmental grooves:**

- (a) Central developmental groove: from the central pit to the mesial triangular fossa.
- (b) Buccal developmental groove: from the central pit to the buccal surface between the mesio-buccal and disto-buccal cusps.
- (c) Distal oblique groove: from the distal triangular fossa going obliquely.
- (d) Lingual developmental groove: this groove joins with the distal oblique groove going between the mesio-lingual and disto-lingual cusps in a cervical direction.

(e) Transverse groove of the oblique ridge: this groove crosses the oblique ridge.

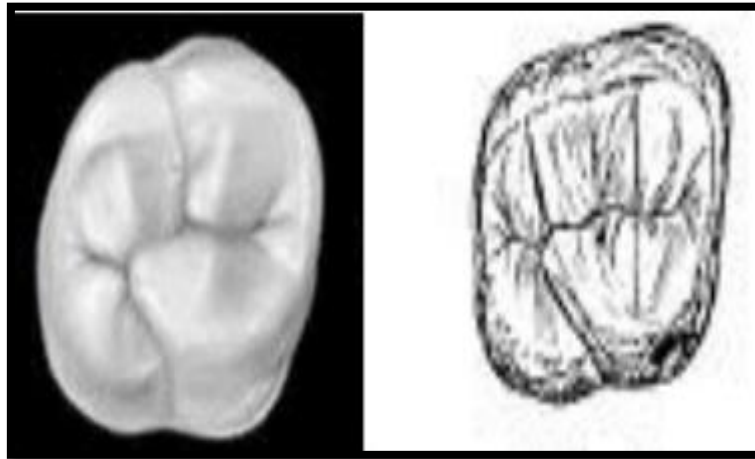
(f) Fifth cusp groove: this groove passes between the fifth cusp and the mesio-lingual cusp.

**7. There are three pits:**

(a) Central pit: it is located at the deepest part of the central fossa at the junction between the central groove and the buccal developmental groove.

(b) Mesial pit: it is located at the deepest part of the mesial triangular fossa.

(c) Distal pit : it is located where the distal fossa and distal triangular fossa join.



# Dental Anatomy



Lecture (11)

---

## **PERMANENT MAXILLARY SECOND MOLARS**

### **Principle identifying features**

- 1.No fifth cusp "cusp of Carabelli " is evident .
- 2.The roots are less divergent and may be coalescent (joined together) .
- 3.Both distal cusps (distobuccal and distolingual cusps) are less developed.
- 4.The crown is smaller in overall dimensions than the maxillary first molar.

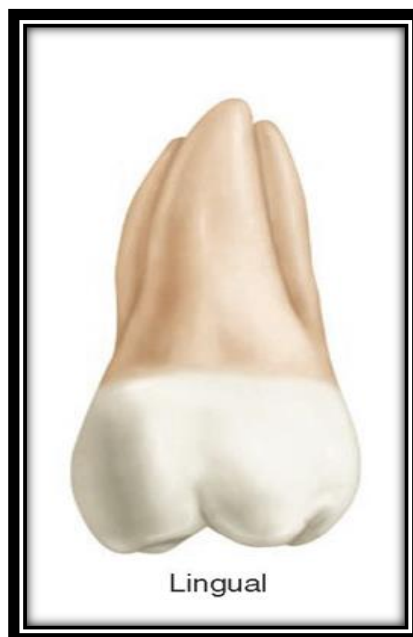### **Buccal Aspect**

- 1.The crown is a little shorter cervico-occlusally (about 0.5 mm) and narrower mesio-distally than the maxillary first molar.
- 2.The distobuccal cusp is smaller and allows part of the distal marginal ridge and part of the distolingual cusp to be seen.
- 3.The buccal roots are about the same length. They are more nearly parallel and inclined distally more than those of the maxillary first molar, so the end of the distobuccal root is slightly distal to the distal extremity of the crown and the apex of the mesiobuccal root is on a line with the buccal groove of the crown instead of the tip of the mesiobuccal cusp as in the maxillary first molar.
- 4.The palatal root is the longest root (1 mm longer than the buccal roots).



**Lingual Aspect**

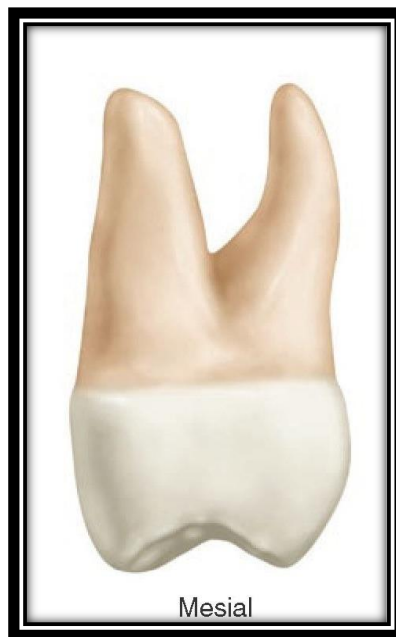1. The distolingual cusp is smaller than that in the maxillary first molar.
2. Part of the distobuccal cusp may be seen mesial to the distolingual cusp (through the sulcus between the mesiolingual and distolingual cusps).
3. No fifth cusp is evident .
4. The apex of the lingual root (palatal root) is in the line with the distolingual cusp tip instead of the lingual groove as was found in the maxillary first molar.





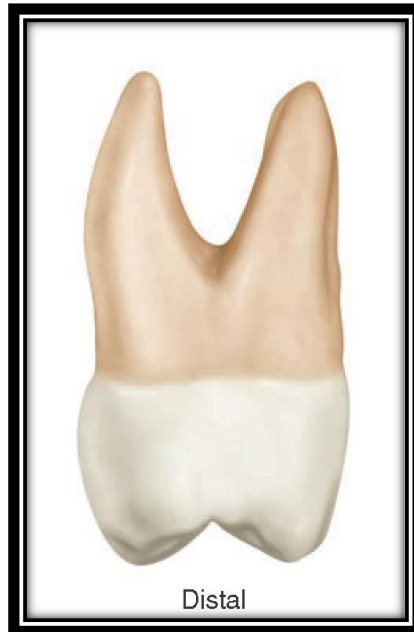### **Mesial Aspect**

1. The buccolingual dimension is the same as that of the maxillary first molar but the crown length is less .
2. The roots are less divergent buccolingually than those of the maxillary first molar being within the confines of the crown.



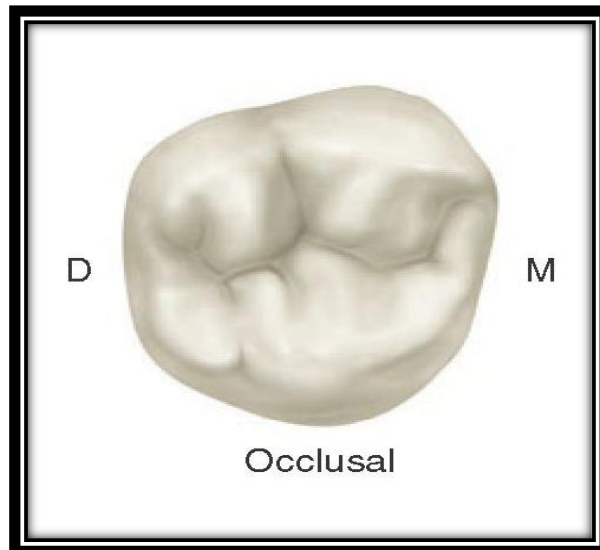
### **Distal Aspect**

Because the distobuccal cusp is smaller than that in the maxillary first molar (more smaller in comparison to the mesiobuccal cusp), more of the mesiobuccal cusp may be seen from this aspect.



### **Occlusal Aspect**

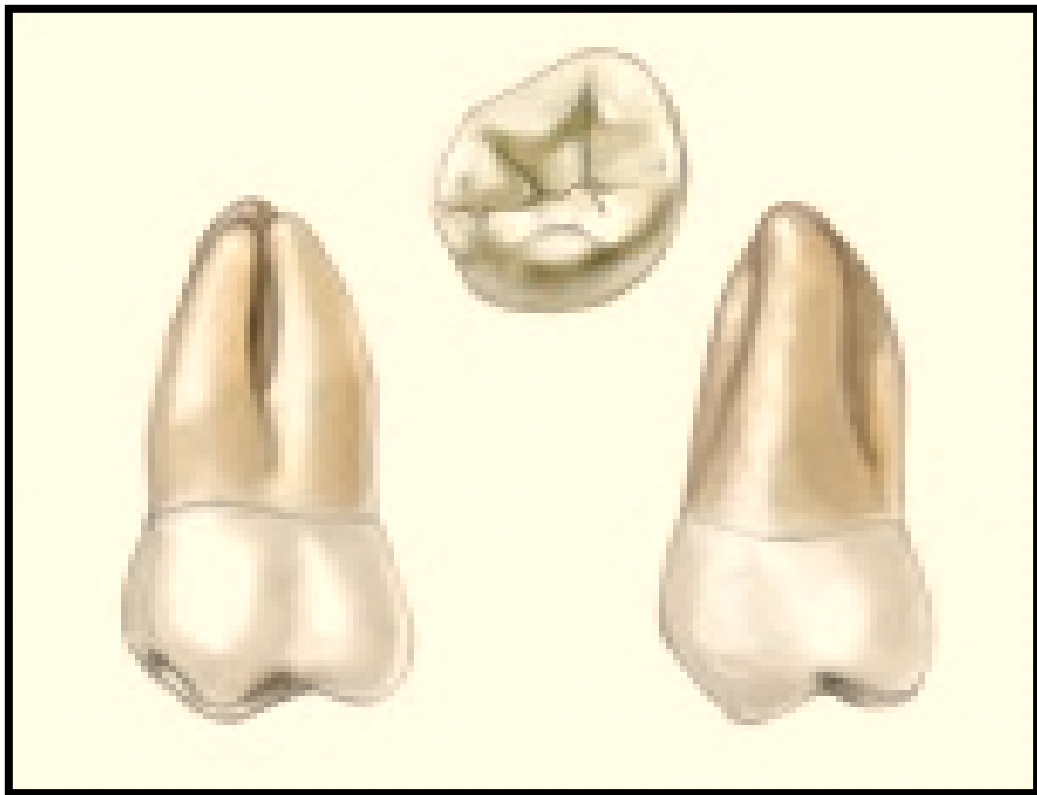
- 1.**The rhomboidal shape of the occlusal aspect is more visible. In comparison with the maxillary the acute angles of the rhomboid are less and the obtuse angles are more.
- 2.**The buccolingual diameter is the same as in the maxillary first molar ,but the mesiodistal diameter is approximately 1mm less.
- 3.**The distal cusps (distobuccal and distolingual cusps) are smaller and less developed than those in the maxillary first molar.
- 4.**No fifth cusp .
- 5.**It is not uncommon to find more supplemental grooves as well as pits on the occlusal surface than are usually found on the maxillary first molar.



## **PERMANENT MAXILLARY THIRD MOLARS**

### **Principle identifying features**

1. It is the smallest maxillary molars.
2. Triangular occlusal outline, the distolingual cusp is very small and poorly developed and may be absent .
3. The roots are shorter ,convergent, often fused and usually are three in numbers .
4. The mesiolingual cusp is the largest cusp.
5. It may have many variations;
  - (a) Heart shaped type with three cusps (most common type).
  - (b) Rhomboidal shaped type with four cusps.
  - (c) One cusp type occlusally (peg shaped).
  - (d) Congenitally missing.



# Dental Anatomy



Lecture (13)

---

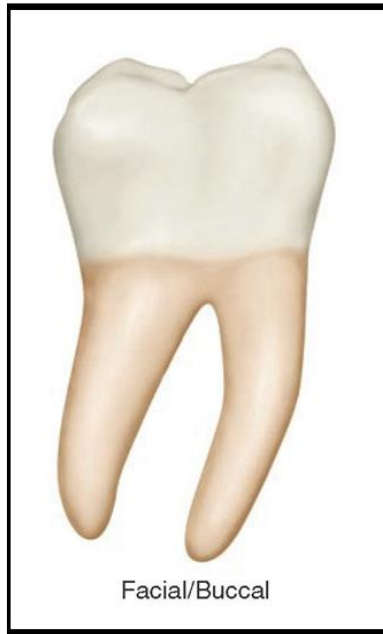## **PERMANENT MANDIBULAR SECOND MOLARS**

### **Principle identifying features**

1. It is smaller than the first molar in all dimensions.
2. It has four well developed cusps: two buccal and two lingual of nearly equal size.
3. There are no distal cusp but the distobuccal cusp is larger than that of the first molar.
4. It has two roots: one mesial and one distal. They are broad bucco-lingually, but they are not as broad as those of the first molar, nor are they as widely separated.

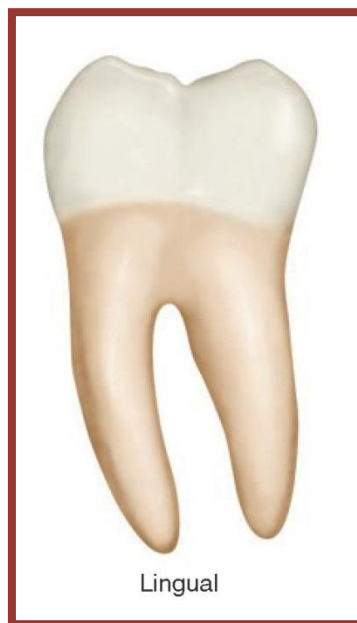### **Buccal Aspect**

1. The crown is shorter cervico-occlusally and narrower mesio-distally than that of the first molar.
2. There is only one developmental groove, the buccal developmental groove which separates between the mesiobuccal and distobuccal cusps.
3. Both mesio-buccal and disto-buccal cusps are nearly equal in their mesio-distal measurements .
4. The roots are shorter than those of the first molar. They are usually closer together and are parallel to each other. They are inclined distally forming an acute angle with the occlusal plane than that found on the first molar.



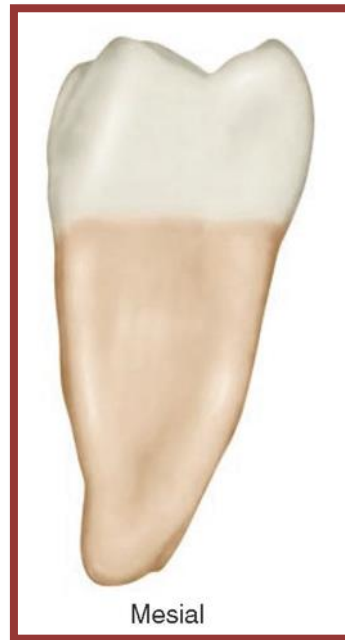**Lingual Aspect**

1. The crown and the roots converge lingually but to a slight degree, therefore:
  - a. Little of the mesial and distal surfaces may be seen from this aspect.
  - b. The mesio-distal dimension cervically is greater than that of the first molar.
2. The contact areas are more noticeable from this aspect and they are slightly more cervically positioned than those of the first molar.



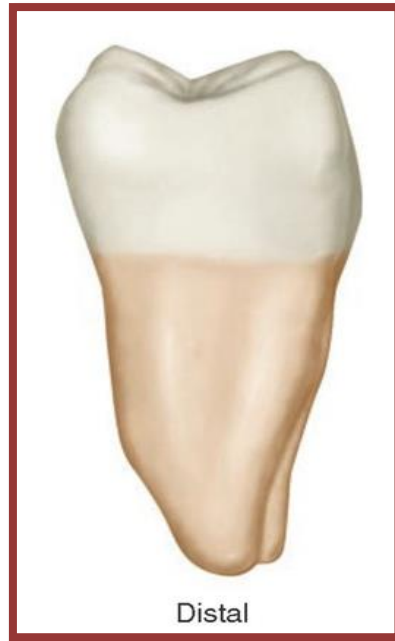### **Mesial Aspect**

- 1.The buccal cervical ridge is less pronounced compared to the first molar .
- 2.The mesial root has a somewhat pointed apex.



### **Distal Aspect**

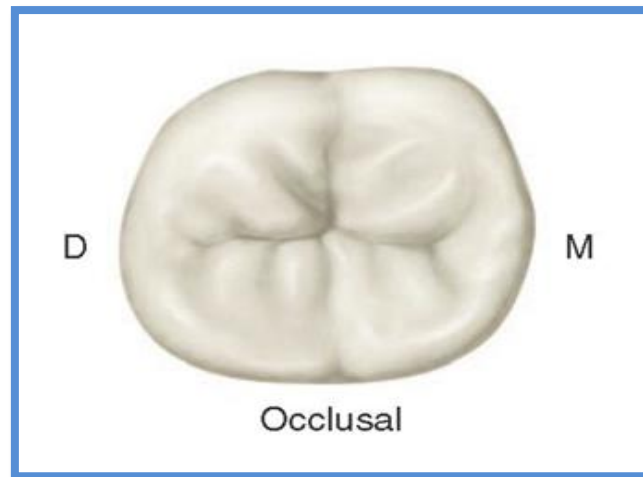
- 1.From this aspect this tooth is similar in form to the first molar except for the absence of a distal cusp and a distobuccal groove.
- 2.The contact area is centered on the distal surface bucco-lingually and is centered between the cervical line and the marginal ridge.



### **Occlusal Aspect**

- 1.**The occlusal outline is rectangular in shape .
- 2.**The distal cusp is not present and there is no distobuccal groove.
- 3.**The buccal and lingual developmental grooves meet the central developmental groove at right angles at the central pit. These grooves form a cross dividing the occlusal surface into four parts that are nearly equal.
- 4.**Unlike the first molar, the occlusal surface is not smooth but is roughened by many supplemental grooves radiating from the developmental grooves .
- 5.**Many teeth show considerable prominence cervically on the mesiobuccal lobe only.

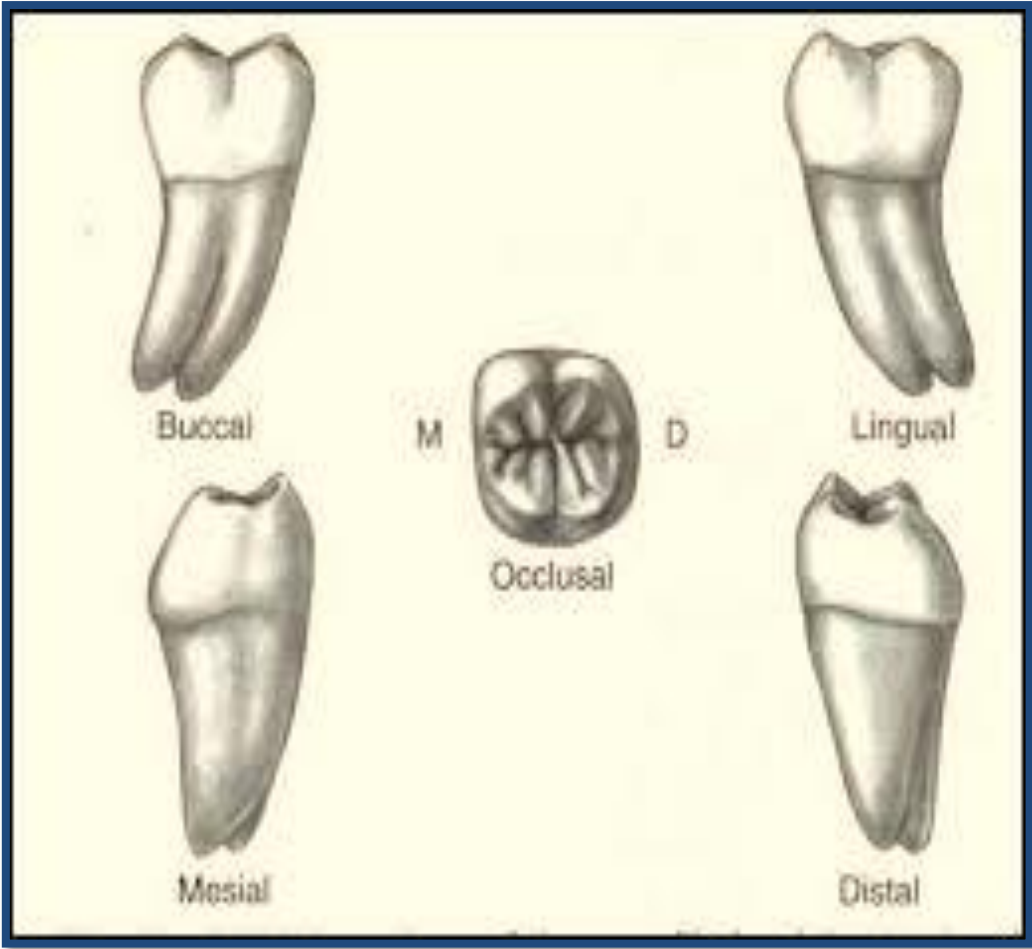




### **Permanent mandibular third molars**

#### **Principle identifying features**

- 1.**This tooth varies considerably in different individuals and present many anomalies both in form and position.
- 2.**Generally this tooth is more similar to the second molar regarding the number of cusps and occlusal form than it does to the first molar.It has a tendency for a more rounded occlusal outline and a smaller bucco-lingual dimension distally.
- 3.**The size of the tooth is variable ranging from large teeth larger than the second molar with five or more cusps to dwarfed (small) teeth.
- 4.**Usually there are two short roots :one mesial and one distal.These are usually shorter than the roots of the first or second molars with greater tendency for distal inclination in relation to the occlusal plane.Sometimes there are more than two roots or the roots may be fused.
- 5.** The tooth could be congenitally missing.



# Dental Anatomy



Lecture (14)

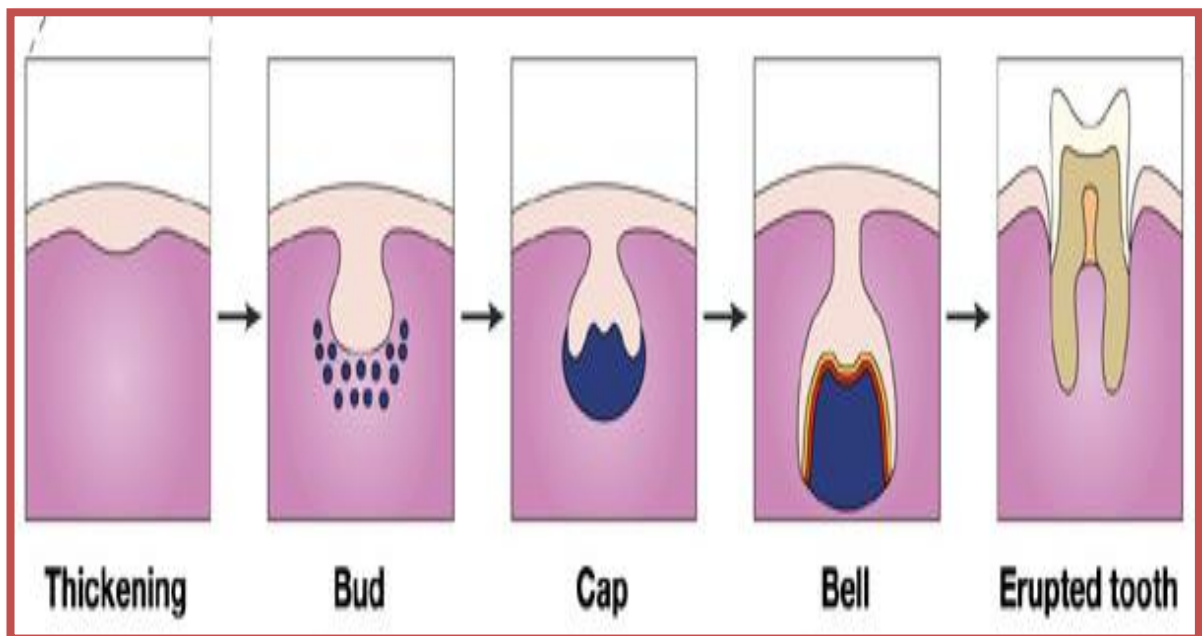
## ***TOOTH DEVELOPMENT***

The development of the crown and the root of the tooth take place within the bone in the jaw. The tooth passes through stages named according to their shapes:

*1. Bud stage.*

*2. Cap stage.*

*3. Bell stage.*

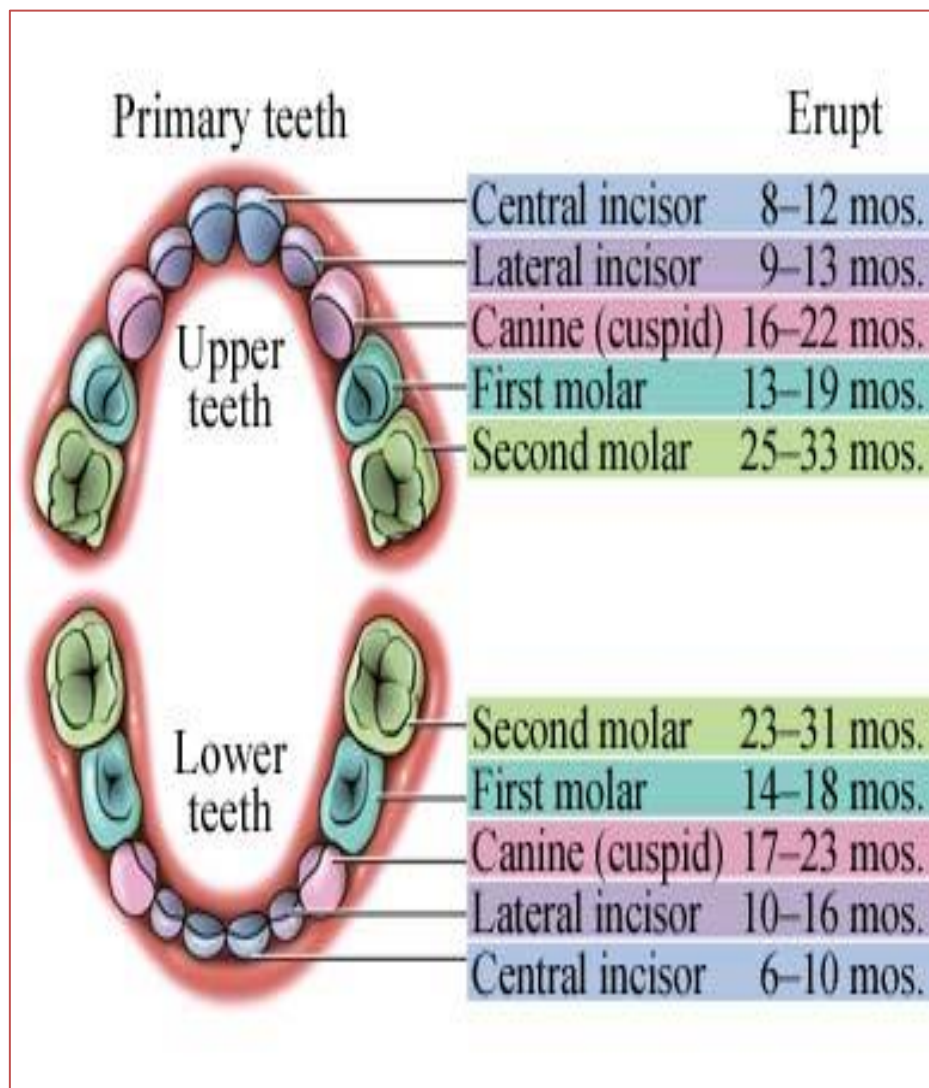


Dental development can be considered to have two components ;(1) the formation of crowns and roots and (2) the eruption of the teeth. After the

crown of the tooth is formed, development of the root portion begins. The root formation not finished when the tooth emerges, however the formation of the root continues after the tooth in use. After the root and crown are formed the tooth penetrates the mucous membrane and enters into the mouth by a process called *eruption*. The eruption of a tooth stops when it occluded with a tooth in the opposing jaw and contacts the adjacent teeth.

**Sequential order of deciduous teeth according to their eruption times**

The predominant sequence of eruption of the primary teeth is central incisor, lateral incisor, first molar, canine and second molar.



## ***Deciduous teeth***

The deciduous teeth are 20 in number. They start erupting at the age of 6.5 months (mandibular central incisor). Their eruption completed at 20-30 months of age (mandibular and maxillary second molars).

### ***The importance of the deciduous teeth***

1. Providing space for the permanent teeth and guiding them into the correct position.
2. Prevent malocclusion.
3. Allow proper mastication
4. Esthetics.
5. Phonetics.

The deciduous teeth roots are fully formed after eruption then after a while resorption to these roots start until exfoliation of the deciduous teeth occurs, followed by the eruption of the permanent successor.

## ***Maxillary deciduous teeth***

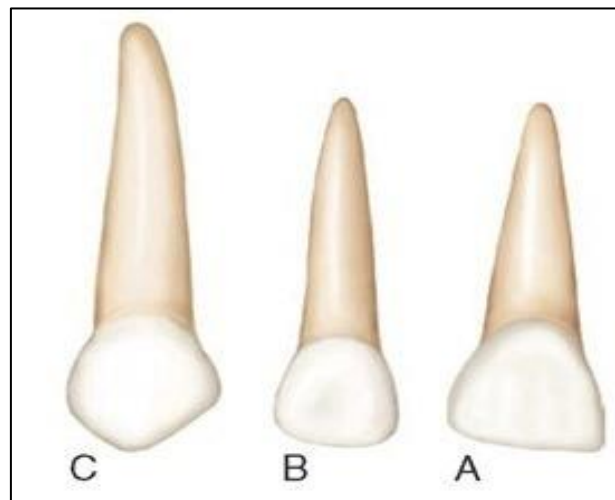
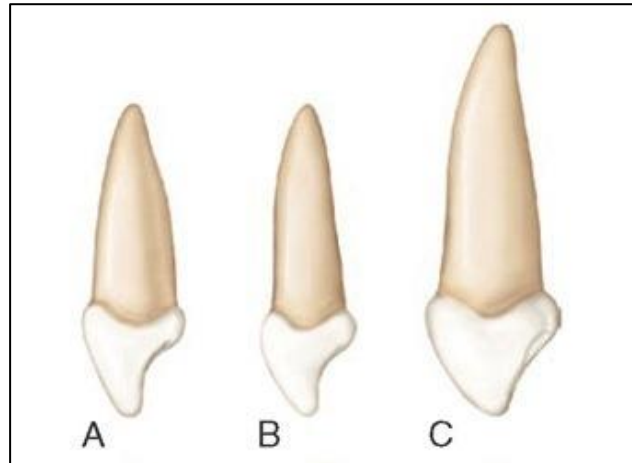
### **Central and lateral incisors**

1. The mesiodistal width is more than the cervico-incisal length (in the maxillary central) while mesiodistal width is less than the cervico-incisal length (in the maxillary lateral) .
2. The root length is greater when compared with the crown length.
3. From the mesial aspect, the crown appears thicker because of the shorter crown length.

### **Canine**

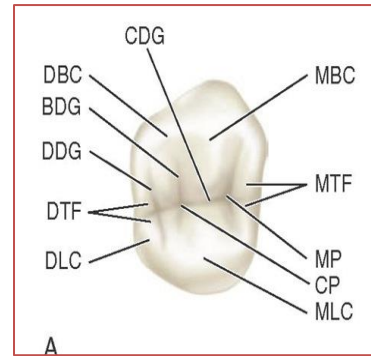
1. From the labial aspect the crown is more constricted at the cervical line, so the cusp and the slopes are seen more developed.
2. The mesial slope of the cusp is longer than the distal slope.

3. The mesial and distal contact areas are at the same level.
4. The root is long and is more than twice the crown length.
5. From the mesial aspect the crown appears thicker labiolingually because of the short crown length.



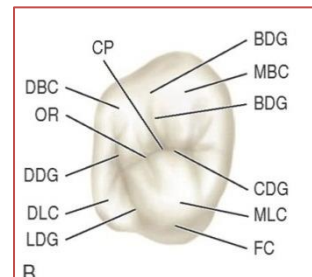
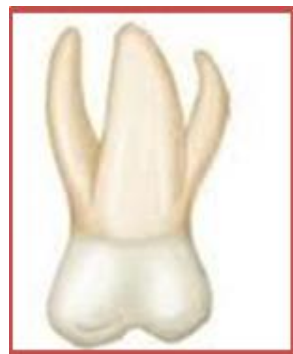### First molar

1. There are four cusps: mesiolingual (largest), mesiobuccal, distobuccal and distolingual (smallest).
2. There are three roots: lingual, mesiobuccal, and distobuccal.



## Second molar

1. There are five cusps (four well developed and one supplemental) which are the mesiolingual (largest), mesiobuccal, distobuccal, distolingual and the fifth cusp (supplemental cusp).
2. There are three roots: lingual, mesiobuccal and distobuccal roots.



## Mandibular deciduous teeth

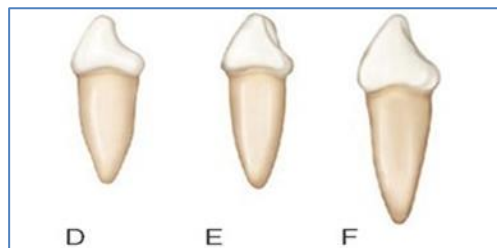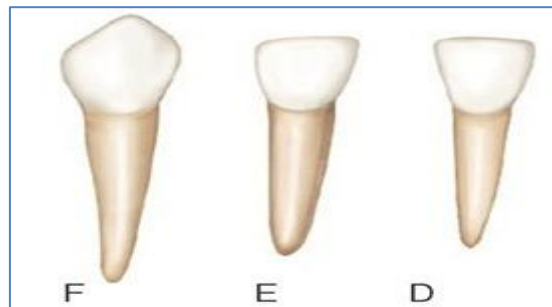### Central and lateral incisors

1. They are wider mesiodistally in relation to their length more than the permanent mandibular incisors.
2. The root length is greater when compared with the crown length.
3. The labiolingual width appears more due to the short crowns length.

### Canine

1. The labiolingual dimension is much less than the deciduous maxillary canine.
2. The cervical ridge is less pronounced than the deciduous maxillary canine.

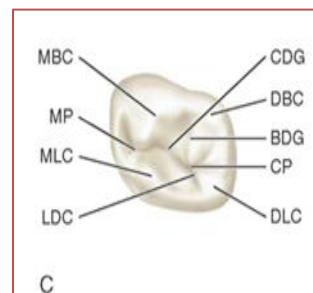
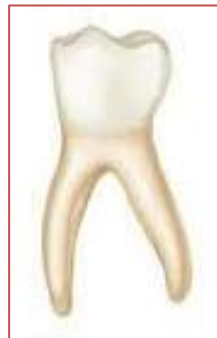3.The distal slope of the cusp is larger than the mesial slope.



### First molar

1. There are four cusps: mesiolingual (largest), mesiobuccal, distobuccal and distolingual (smallest).

2. There are two roots: mesial and distal roots.

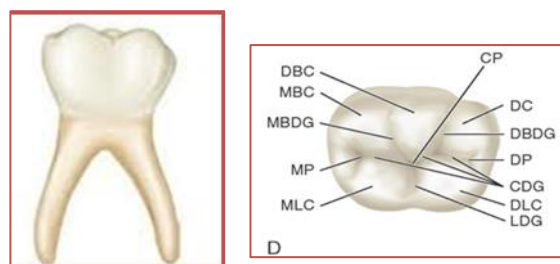


### Second molar

1. There are five cusps: mesiolingual, mesiobuccal, distobuccal, distolingual and the distal cusp.

2. There are two roots: mesial and distal roots.





## ***Principal differences between deciduous and permanent teeth***

### **General differences**

1. The deciduous teeth are 20 in number while the permanent teeth are 32 in number.
2. The deciduous teeth are smallest in all dimensions.
3. The deciduous teeth show less morphological variations.
4. The enamel of the deciduous teeth is whiter and more opaque so they are whiter than the permanent teeth.
5. The enamel of the deciduous teeth is thinner (0.5-1mm), while in the permanent teeth it is (1.5-2.5mm).

### **Crown differences**

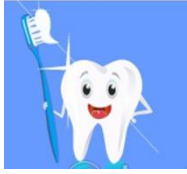1. The crowns of the deciduous are more constricted at the cervix.
2. The cervical ridges in all deciduous teeth are more prominent.
3. The intercuspal distance of the deciduous teeth is more constricted buccolingually.
4. The crowns of the deciduous anterior teeth are wider mesiodistally as compared with the crowns width.

### **Root differences**

1. Lack of root trunk in the deciduous molars.
2. The roots of the deciduous teeth are shorter, weaker and narrower.

**3.**The roots of the deciduous teeth are longer in proportion to the crown.

**4.**The roots of the deciduous molars are wider than the crown to allow more room for the development of the successor permanent teeth.



# Dental Anatomy

Lecture (15)

---

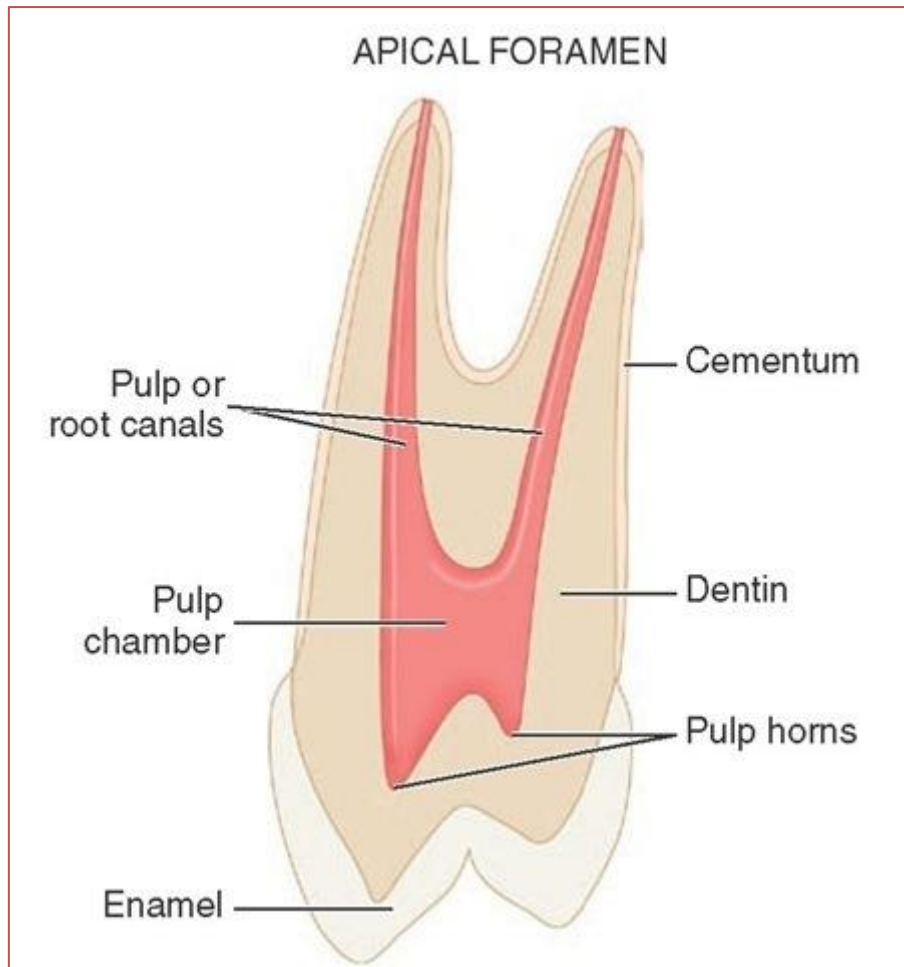
## ***PULP CAVITIES***

The dental pulp is the soft tissue of the tooth. The pulp occupies the internal cavities or spaces of the tooth which include the pulp chamber and the pulp canal (root canal).

The shape of the pulp cavities correspond to the external outline form of the tooth (the shape of the pulp chamber corresponds to the shape of the crown whereas the shape of the pulp canal corresponds to the shape of the root). The size of the pulp cavity depends on the age of the tooth and history of trauma.

At the apical end of the root there is an opening through which the neurovascular bundle enters the pulp called the *apical foramen*.

The pulp horns are projections or prolongations of the pulp in the roof of the pulp chamber that correspond to the major cusps or lobes of the crown.



## **PULP CAVITIES OF THE MAXILLARY TEETH**

### **Maxillary central incisor**

The pulp chamber is very narrow labiolingually while it is wide mesiodistally.

In cross section, the pulp chamber is triangular in outline with the base of the triangle at the labial aspect.

### **Maxillary lateral incisor**

The pulp chamber anatomy is similar to that of the central incisor. In cross section, it may be triangular, oval or round.

**Maxillary canine**

The pulp cavity is much narrower mesiodistally than labiolingually.

In cross section, the shape of the pulp space is oval.

**Maxillary first premolar**

In cross section, the pulp chamber is kidney-shaped outline form.

**Maxillary second premolar**

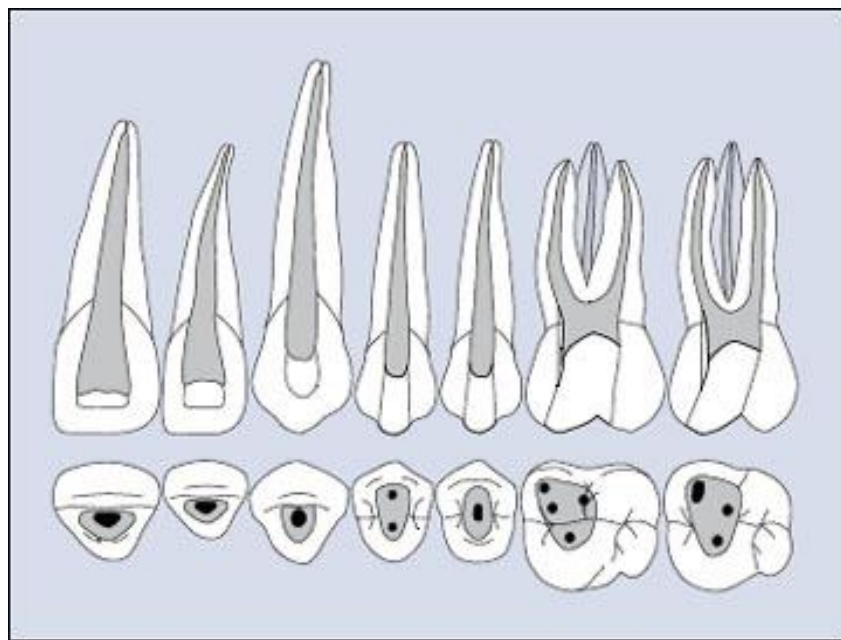
In cross section, the pulp chamber is oval in shape.

**Maxillary first molar**

In cross section, the pulp chamber is rhomboidal in shape.

**Maxillary second molar**

The pulp chamber anatomy is similar to that of the maxillary first molar but the chamber is much smaller in mesiodistal section.



## **PULP CAVITIES OF THE MANDIBULAR TEETH**

### **Mandibular central incisor**

The tooth usually has one canal but two canals may be found. The pulp cavity is narrow labiolingually while it is wide mesiodistally.

In cross section, the pulp chamber may be round, oval or elliptical in shape.

### **Mandibular lateral incisor**

Similar to the central incisor but larger in size.

### **Mandibular canine**

The pulp chamber is similar in size and shape to that of the maxillary canine but tends to be a little shorter. In cross-section, it is oval in shape.

### **Mandibular first premolar**

This tooth mostly has one canal, but two canals are possible. The pulp horn of the buccal cusp is prominent but that of the lingual cusp is usually small or sometimes completely absent.

In cross-section, the pulp cavity may be round or elliptical.

### **Mandibular second premolar**

The pulp horns are more prominent than those of the first premolar.

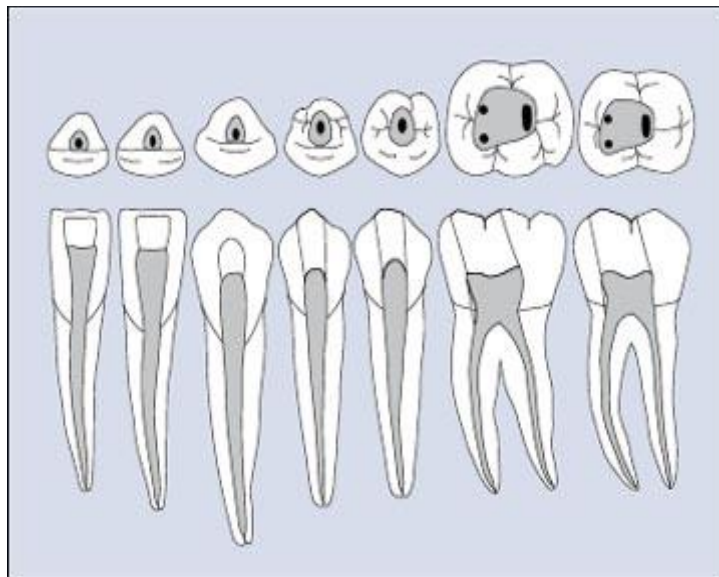
In cross-section, the pulp cavity may be rectangular or oval.

### **Mandibular first molar**

This tooth usually has three canals. The mesial root has two canals while the distal root has one large canal. Sometimes the distal root has two canals. In cross-section, the pulp cavity is quadrilateral in form.

### **Mandibular second molar**

The pulp chamber anatomy is similar to that of the mandibular first molar.

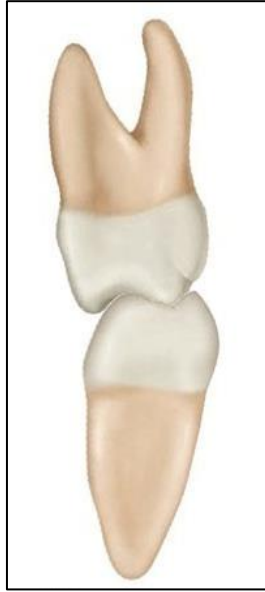

### **OCCUSION**

Occlusion refers to any contact relationship between the maxillary and mandibular teeth during function and parafunction.

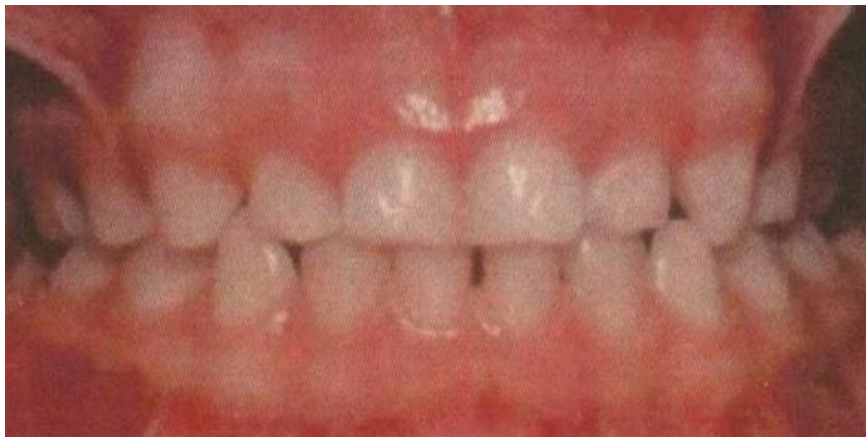The arch form of the maxilla tends to be larger than that of the mandible. This results in the maxillary teeth overhanging the mandibular teeth when the teeth are in centric occlusion (the position of maximal intercuspation).

During maximum intercuspation, the mesiolingual cusp of the maxillary molars occludes with the central fossae of the mandibular molars.



**Occlusion in deciduous dentition**

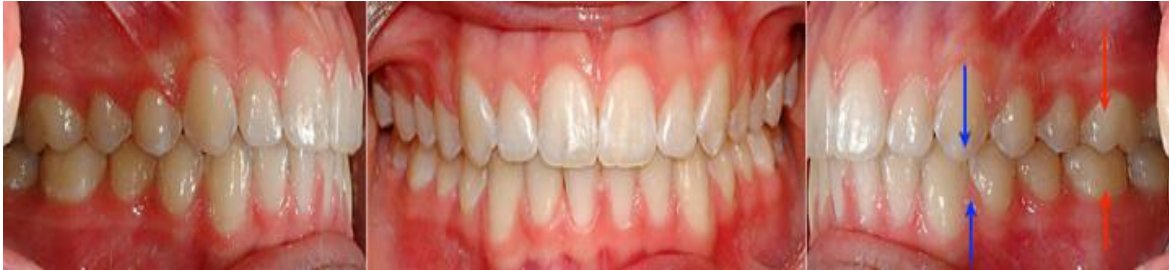Each tooth occludes with two teeth of the opposing jaw except mandibular central and maxillary second molar. Occlusion is supported and made more efficient after eruption of the permanent first molars.





### *Occlusion in permanent dentition*

With the exception of mandibular incisors and maxillary third molars, each tooth contacts two antagonist teeth in the opposing arch.



A normal dentition is characterized by an ideal alignment of the upper and lower teeth and by an intermaxillary relationship (between both jaws). The upper canine is aligned with the embrasure between the lower canine and the lower first premolar (blue arrows). The first corner (mesiobuccal cusp) of the upper first molar is aligned with the center (mesiobuccal groove) of the lower first molar (red arrows). The maxillary arch midline fits with the mandibular arch midline.